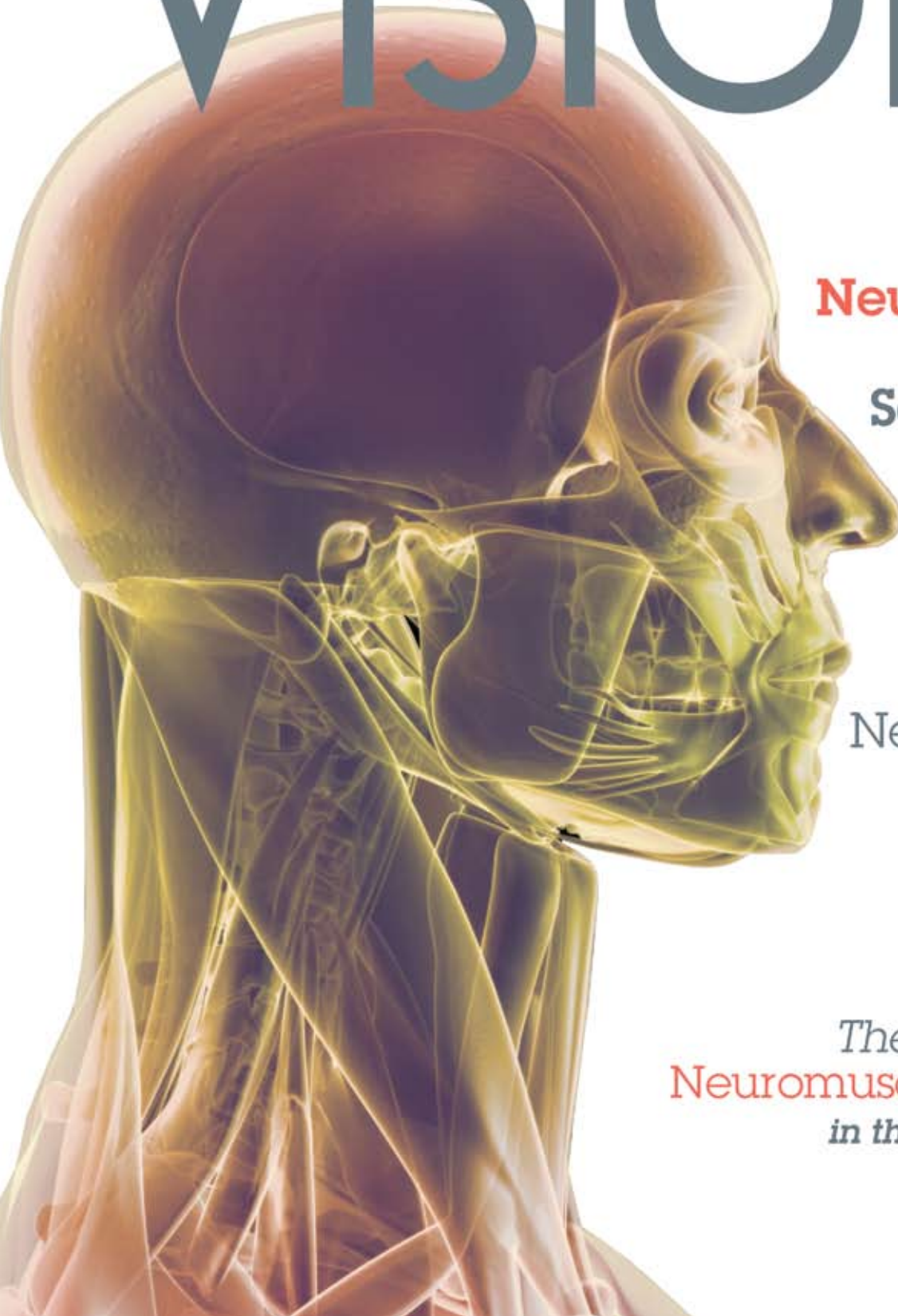


LV I ■ ■ *Changing Dentistry. Changing Lives.* Visions



**Why Is
Neuromuscular
Dentistry
So Important?**

Neuromuscular
Dentistry and
**Obstructive
Sleep Apnea**

*The Relevance of
Neuromuscular Dentistry
in the New Millennium*

MACSTUDIO
BY MICRODENTAL LABORATORIES



Kimble Slonaker
2011 MACVENEERS MODEL SEARCH FINALIST

DENTISTRY BY
Dr. Trevor Murray, Lafayette, IN

MACSTUDIO MICRODENTAL ADVANCED COSMETICS

Kimble's story began with a collaborative approach to smile design. Multimedia and photo-interpretation was used to enhance communication and define preferences. Wash bake methods, internal effect pastes, and porcelains of varied translucencies were harmonized to create beautiful, intrinsic qualities. Cutback and layering techniques, pioneered by MicroDental's CTO and AACD accredited CDT Lee Culp, resulted in individualized, anatomical subtleties for each restoration.

From full-mouth rejuvenations to single tooth restorations; MACVENEERS™ to crowns, bridges, implants and removables; MicroDental's MACSTUDIO team can help create A SMILE FOR EVERY STORY™.



MicroDental.com/macstudio
800.229.0936

MICRODENTAL
LABORATORIES

contents

Why Is Neuromuscular Dentistry So Important?	6
Why, we as a Laboratory embrace Neuromuscular Dentistry	10
Ask Heidi	14
Educated Team = Educated Patients	18
Temporomandibular Disorders	20
What was your experience TENSing?	33
Signs and Symptoms of NM	36
A Neuromuscular Perspective on Removable Dentistry	40
The Relevance of Neuromuscular Dentistry in the New Millennium	44
Neuromuscular Dentistry and Dental Sleep Medicine A Marriage of Mutual Advantage	52
New Programs at LVI	60
The Keys to Understanding NM and OSA Part VII	64
HRIQ	68



on the cover

Why Is Neuromuscular Dentistry So Important?

Several surveys taken on this subject indicate that perhaps as much as 80% of the population is not in their physiologically correct biting position. Although this does not mean that all of them have symptoms that need treatment, as many as half of them may have problems associated with their pathologic position. How could that be?

Muscle and Pain Facts:

Approximately 90% of pain is caused by muscles.

Editor In Chief: Dr. Heidi Dickerson

Executive Editor: Dr. William G. Dickerson

Creative Directors: Julie Grabusnik and Kara Wagner

Design Production Director: Joe Thomasula

The Las Vegas Institute for Advanced Dental Studies (LVI) publishes LVI Visions. Please send any comments or suggestions to 1401 Hillshire Drive, Suite 200, Las Vegas, NV 89134. Telephone (888) 584-3237 or (702) 341-7978 • www.lviglobal.com.

Copyright ©2012 – Las Vegas Institute for Advanced Dental Studies. All rights reserved. No part of this publication may be reproduced in any form without written permission from the Las Vegas Institute for Advanced Dental Studies. LVI does not verify any claims or other information appearing in any of the advertisements contained in this publication.

contributors



William G. Dickerson, DDS, LVIM

Bill is the Founder and CEO of the Las Vegas Institute for Advanced Dental Studies (LVI Global). He is one of the most influential dentists in the world, by spanning the globe with Continuing Education for all aspects of dentistry. As an author, clinician and international lecturer, Bill has inspired dentists to Change Dentistry and to Change Lives.



Anne-Maree Cole, BDS, LVIM, MICCMO

Anne-Maree is the Director of LVI Global Australia and a past president of the IACA. As a perpetual student, she has taken more courses at LVI than anyone on record!



Heidi Dickerson, DDS, LVIM

Heidi is the President of North American/ Australian Operations at LVI Global. She has helped share the Neuromuscular philosophy by her clinical teachings and her international lecturing. In 2010, she was named one of the Top 25 Women in Dentistry.



Minette Galura-Boquiren, RDA

Due to her profound interest in Neuromuscular Dentistry and Aesthetics Minette has become the first Clinical Affairs manager at LVI.



Norman Thomas, DDS, PHD, O. Path. MD: Bsc (Hans. Anat. Physiol.), FRCD; FADI, MICCMO, DAAPM, CMAc

Norman is the Director of Neuromuscular Research at LVI Global. He is a Professor Emeritus at the University of Alberta. Norman is one of the smartest men in dentistry!



Barry C. Cooper, DDS

Dr. Barry Cooper received his D.D.S. degree in 1963 from Columbia University School of Dental and Oral Surgery. He is currently a clinical professor, Division of Translational Oral Biology of the State University of New York.



Mark Duncan, DDS, FAGD, DICOI, LVIF

Mark is the Clinical Director at LVI Global and serves as an IACA board member. He is involved in teaching the Core 1-7 courses at LVI. His goal is to advance the understanding of the science behind Neuromuscular Dentistry.



John S. Pawlowicz III, DMD, MICCMO, LVIF

John is a graduate of the University of Pittsburgh School of Dental Medicine and passionately maintains private practice in Butler, Pennsylvania. He instructs several core courses at LVI as well as the Optimal Denture course.



Shamshudin Kherani, DDS, FAGD, LVIM, FICCMO

Sam has served as a past president of the IACA. He maintains a private practice in Vancouver, B.C.



Tim Twigg, Bent Erickson & Associates

Tim is the President of Bent Erickson & Associates. For over 30 years, the company has been recognized as the leader and most trusted name for human resources, products, services, and support for health care providers.

Technology **4** Medicine™

LIGHTWALKER

Dual Wavelength, Er:YAG & Nd:YAG

The 2 leading **LASERS**, 1 superior package. Invest Less. **Do More.**



Best of Class
Pride Institute

"red dot" Design Award 2012
Superior Design & Technology



red**dot**



Dentistry Today's
Top 100 Products

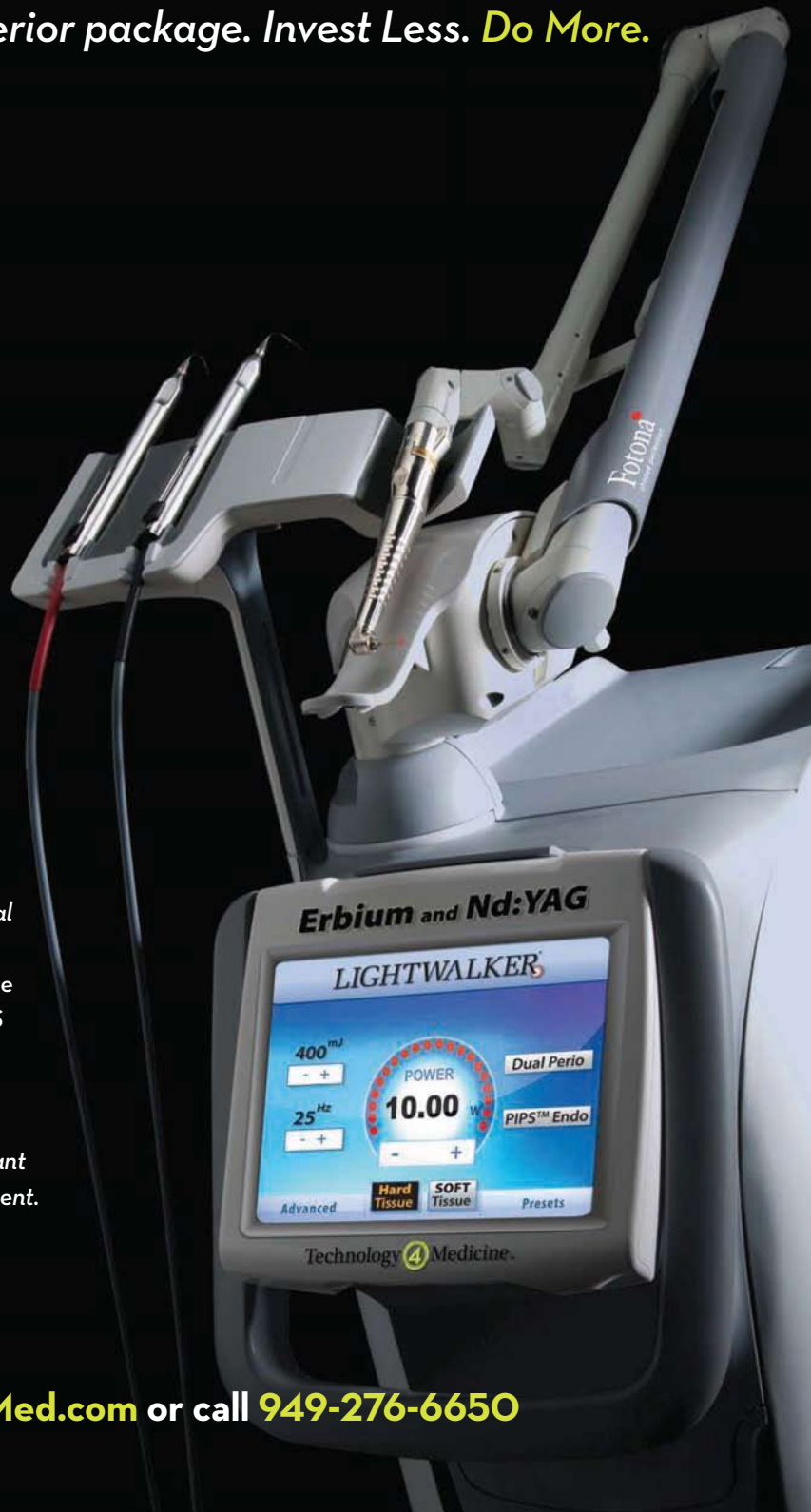PIPS™ - Photon Induced Photoacoustic Streaming™

A Dramatic Breakthrough in Endodontics
Available Exclusively with the Lightwalker

"I have been using PIPS for over a year on most of my cases. Herb Schilder stated that endodontic cases had the potential of 100% success minus X. The X factor being the complexity of the root canal system and the operator's ability to manage the cleansing and shaping of that system. I believe that PIPS enhances my ability to reduce this X factor to as close to 0 as is possible today. The Dual Wavelength LightWalker has also proven to be very valuable to my implant cases. Having both the Er:YAG and the Nd:YAG in one system is an important advancement which allows you to get more for your investment. I recommend this product without reservations."

Bryan M. Beebe D.D.S.
Endodontist, Sarasota, FL

For More Information, visit www.T4Med.com or call **949-276-6650**





WHY IS NEUROMUSCULAR DENTISTRY SO IMPORTANT?

William G. Dickerson, DDS, FAACD, LVIM

Several surveys taken on this subject indicate that perhaps as much as 80% of the population is not in their physiologically correct biting position. Although this does not mean that all of them have symptoms that need treatment, as many as half of them may have problems associated with their pathologic position. How could that be? **Why would such a large part of the population be potentially pathologic?** Truth is it's only the Western population. If someone examines the primitive cultures out there, they do not have much malocclusion. Those of you familiar with Dr. Weston Price's work are aware of that.

However, modern society has created the situation that causes so many people to have a biting position that is not in their physiologically comfortable position. The big question is why? **What is it that caused so many developmental problems?** This has been thoroughly explained in the lifetime of work by the late Dr. Jim Garry. Jim helped

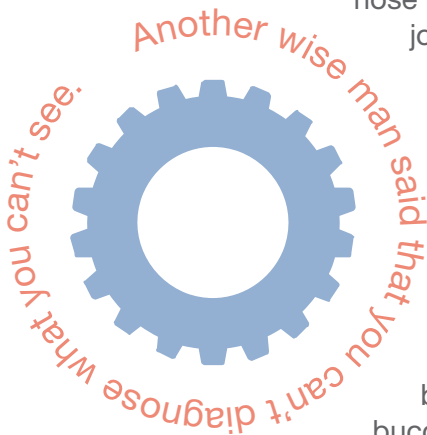
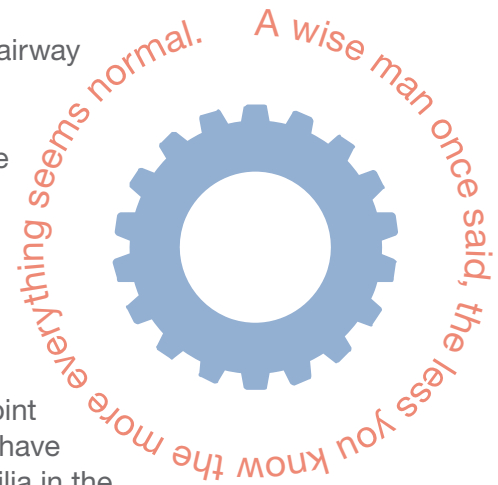
so many people in his life, either directly or indirectly, by teaching dentists to recognize the signs and symptoms of airway obstruction. All I know in this area came from this great man and one of my greatest honors was when Jim willed me his lifetime of work and presentations.

Yes, the causative factor in most occlusal disharmony cases is airway obstruction during the developmental stages of a child. If we, as physicians of the mouth, can determine those signs and symptoms and then correct the problems, we can prevent these children from growing up to be occlusally compromised adults. **This could prevent many people from a lifetime of suffering from craniomandibular disorders (CMD).**

So many children in Western society have snotty runny noses due to allergies. The most common food allergen is cow's milk, followed by chocolate and cola. Wheat is not far behind. The point is the environmental situation causes many western children to have allergies. This causes the mucous buildup which prevents the cilia in the nose from doing their job. The cilia beats at 10 to 20 times a second, and its job is to transfer the bacteria down into the throat to be swallowed and then eliminated out of the body in our waste. If the cilia can't do its job, the bacteria sit in the back of the throat and cultures, causing the tonsils and adenoids to work overtime to fight the bacterial buildup. This causes hypertrophy of the tonsils and adenoids which lead to the patient's difficulty in breathing through their noses. **The patient then becomes a mouth breather.**

So you're thinking, so what? Why would being a mouth breather cause malocclusion? This is really quite simple. There is a constant battle in arch development between the sphincter action of the buccinator muscles and the outward forces of the tongue. **When a patient breathes through their mouth, the tongue is placed in an abnormal position and does not support the optimal maxillary arch form.** Because the tongue is removed from the picture, the buccinator muscles win the war and the buccinator constricts the arch. The constriction of the arch creates less room for the teeth causing malocclusion. Also, in a mouth breather, the tongue may rest on the posterior teeth and prevent them from completely erupting, causing a bicuspid drop off. This requires the patient to retrude their mandible in order to get the back teeth together, causing a deep overbite.

With the bite now over closed and the mandible retruded, there is even less room for the tongue when the mouth is closed. It forces the tongue back, shutting off the airway. **So in order to breathe, they have to open their mouths so the tongue can move forward.** These individuals become chronic mouth breathers for the rest of their life. There is also a 75% overlap of CMD patients and OSA (obstructive sleep apnea). There are common origins in the etiology of both of these conditions, which is why co-treating these patients is so important. OSA is a killer and nothing could be more powerful for dentists than saving someone's life.



Of course there are many other symptoms that can be created by airway obstruction, anterior open bite, cross bite, class III, class II, and too many others to talk about in this article, but hopefully the reader understands the stomatognathic imbalance that can occur when there is a disharmony between the forces acting upon the dental arch. **It's when the arch reaches a neutral position between the forces of the buccinator muscles and tongue that the arch stabilizes.**

With the constriction of the arch comes a high palate. The high palate creates a reduction in turbinate space. **With the reduction in the turbinate space, any inflammation of the sinus will cause enough swelling of the tissue to restrict or block the airway and the ability of the patient to breath through their nose.** Children with airway obstruction problems resulting in malocclusion and high palates, become adults with chronic airway problems due to the reduction in turbinate space, many times requiring turbinate reduction surgery.

So why do these children grow up to be adults with TMD problems? When the arch is not formed properly, the mandible is not positioned properly either. If the mandible is not in its comfortable position, then their muscles are forced into a chronic contraction state (hypertonicity). That chronic contraction causes muscle pain. Dr. Janet Travell (JFK and Lyndon Johnson's physician) years ago stated that 90% of pain comes from muscles. **For every muscle that is in chronic contraction, there are antagonist muscles that are forced to contract as well.** It's why neck and shoulder pain are often associated with a bad bite.

The key for the modern practicing dentist is to be able to recognize the signs and symptoms in children to prevent them from becoming chronic adult pain patients as adults, which require complex restorative or orthodontic treatment to help them. **The signs and symptoms in children will still be there as adults.** Then it's up to the dentist to learn the fundamentals of how to diagnose the problems and treat them accordingly.

Step one. *Realize that as dentists we can have a dramatic affect on the patient's health and happiness and even their lifespan.*

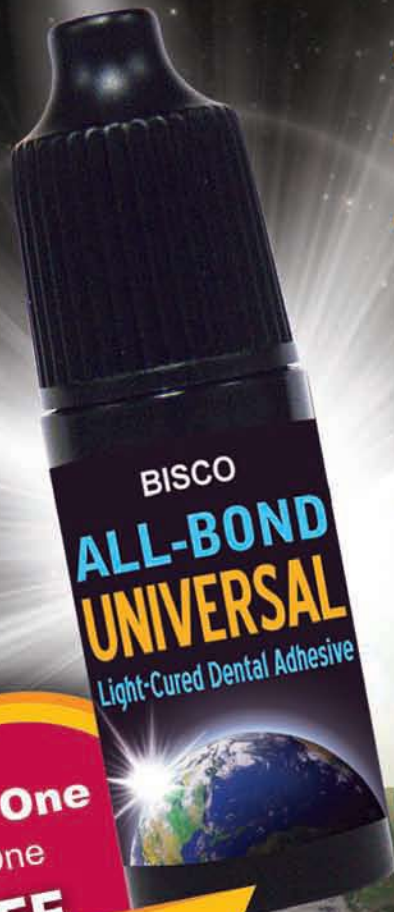Step two. *Learn the early signs in children to prevent a lifetime of problems.*

Step three. *Learn the techniques to treat children and adults with pain causing occlusal disharmony problems.*

A wise man once said, the less you know the more everything seems normal. Another wise man said that you can't diagnose what you can't see. **Unfortunately, many uninformed dentists can't see the signs and symptoms that dentists educated in this area can see.** Their reaction is to accuse the educated dentists of over treating when in actuality, they are undertreating and misdiagnosing. Commit to becoming the best you can be by incorporating neuromuscular treatment and sleep dentistry into your practice and change your life and the lives of your patients.

TRULY UNIVERSAL

- Total-etch, self-etch, selective etch
- Directs
- Indirects
- No activator
- Total compatibility



BISCO's **ALL-BOND UNIVERSAL™** is a single-bottle adhesive combining etching, priming and bonding. As a universal adhesive it can be used with both direct and indirect restorations and is formulated to be compatible with light-, dual- and self-cured materials. **ALL-BOND UNIVERSAL** provides the tradition of bonding excellence in a single bottle.

Buy One
Get One
FREE

NEW!

Order Today:

1-800-BIS-DENT
(800-247-3368)

www.bisco.com

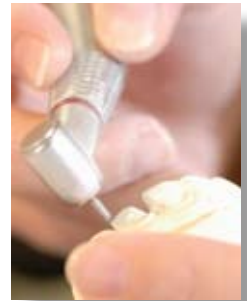


Discounts cannot be combined with any other offer. U.S. customers only.
Promo code: 12LV12. Offer ends 6/15/2012.

“Why, we as a Laboratory embrace Neuromuscular Dentistry.”



To our laboratory, neuromuscular dentistry is much more than a bite; it is a process, a step-by-step meticulous management of a bite. The concepts and components of Neuromuscular Dentistry have provided the occlusal guidelines for our lab for the past twelve years.



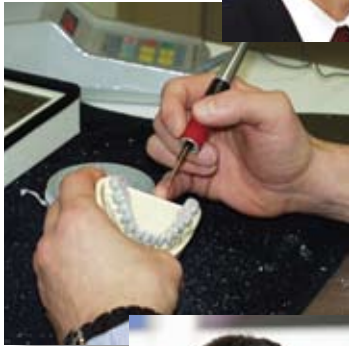
When neuromuscular protocol is followed, we, as a lab, become much more conscientious to the details of the case, as well as the dentist and their team.

Aesthetics are important; but paramount to the success of the case is the health of the patient. If a new vertical increase is necessary for the advancement of the patient's health, the stabilization of that vertical increase becomes a priority. The techniques used with NM dentistry connect the dots as this stabilization takes place. Doctor, lab and patient form the perfect triad for success with this method.



In our laboratory, the NM approach guides all the cases we receive and gives us the confidence that we are handling these cases with the greatest care and knowledge possible.

Michael L. Milne, CDT, LVIM
MicroDental & DTI Laboratory
LVI Master Technician





As a dental laboratory serving clients across North America for more than 40 years, we have been involved with many cases involving TMD/TMJ. Over the past 20 years, an increasing percentage of these have involved dentists employing neuromuscular principles.

Based on regular long-term feedback from our clients and their patients, our experience with neuromuscular cases over the years has been universally successful. We have seen, and continue to see, a wide variety of severe problems related to TMD resolved successfully by neuromuscular-based restorative treatment (after other philosophies failed to provide the patient with relief).

The keys to success have been the LVI training, which is readily available to both clinician and technician on all aspects of neuromuscular treatment and the commitment from all parties involved to regularly and effectively communicate throughout the restorative process.

It is an exciting time to be involved in dentistry, and neuromuscular modalities are a key part of bringing new and rewarding treatment options and outcomes to the patient base.

Ulf Broda, RDT, CDT
Aurum Ceramic Dental Laboratories
Manager, Cosmetic and Neuromuscular Department

As NM grows in acceptanceso does the demand for highly trained technicians that understand NM occlusion that are motivated and willing to work hand in hand for ideal results with their dentist clients. We have found NM practicing clinicians to be very motivated to learn the best and newest techniques.

There are many aspects of any dental procedure that make it "successful". The final result aesthetics (how the patient perceives the end resulting) , long term function, predictability, ease of use, ease...BUT it must also be easy to implement and understandable by the average general dentist that wants to incorporate occlusal rehabilitations into their day to day practices. It can't be something that just a chosen few that have "amazing" talents can do...It must be easily grasped. We have found NM to fill this void for many and helped thousands of patients worldwide in the process (that may have never been helped otherwise).



As a highly trained CR lab for over 30 years...training closely with the "best of the best" in the CR modality we saw many unpredictable failures and were in search of something new and more functionally repeatable that the average dentist could use in their practice.

Bob Clark, CDT, LVIM, LVI Master Technician
Williams Dental Laboratory



NM Dentistry is the path I chose because it's Neuro-responsible.

I began my career as a dental lab tech when I was 19, I turn 59 this year and I have seen a lot!

Alongside this I pursued my studies as a figurative sculptor, studying anatomy, the HUMAN FORM and function.

Whole body dentistry only came about with Neuromuscular principles and a raise in consciousness. I was hooked because it finally all made sense. Dentists can do so much these days to help their patients. NM dentistry has given them tools to see the BIG picture the HUMAN FORM and function.

This is why I feel very good as a lab tech supporting NM dentists.

Cynthia Wright, CDT, LVI Master Technician

In the year 2000 I sold my dental lab of twenty years in Chicago and moved to Florida to be near my family and of course the beach. I did this because I was tired and bored going through the motions making a lot of molars. Because of our Dawson training we did our share of full mouth cases; however the frustration level was profoundly high. I felt like I had no idea what was going on during the process of restoration and the outcome was never predictable.



In 2004 I wandered into LVI and sat down in a class that completely changed everything. The class was "the neuromuscular technician". Before I could ask the question "why" I was shown with measurements and computer verified proof that our bite was spot on! The lab I now have works exclusively with LVI grads and those on the journey. When we do a full mouth or full arch case I completely understand the entire process and can see the verification with every step. Every week we get compliments on how we changed someone's life with their new smile and their new life without pain. We get to do the most wonderfully complicated cases. We have been a part of successfully restoring cases that other non-LVI dentists would not even touch.

While over two thousand dental labs closed last year, in 2011 our revenues were up. Our level of job satisfaction and respect from our clients is profoundly increased from the old days. For the first time in over thirty years I can truly say I love my job on a daily basis.

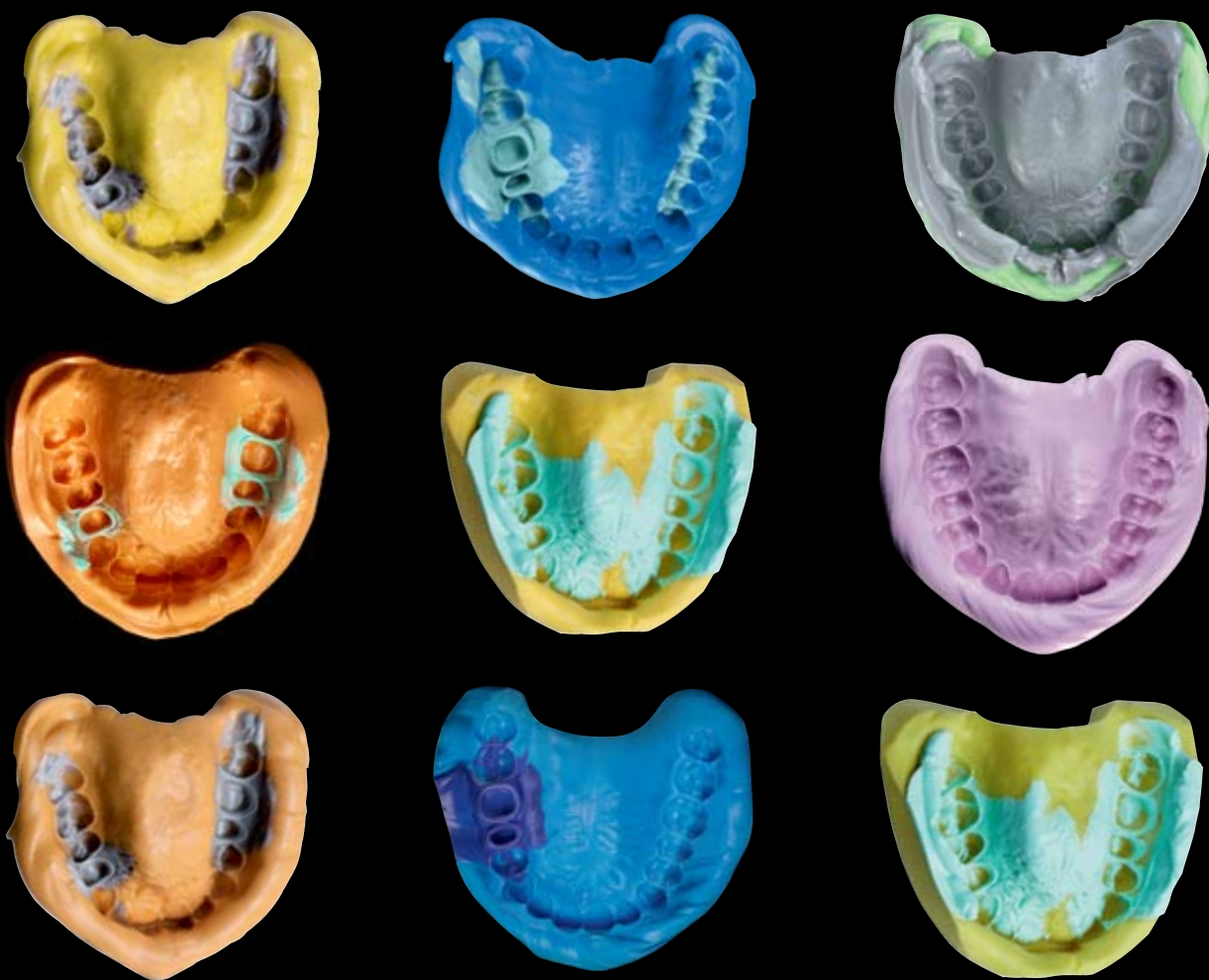
James Kash, CDT

Course Dates:

Neuromuscular Technician ■ October 20-22, 2012

Full Mouth Waxing ■ December 1-3, 2012

Kettenbach – The Direct Source for all your **Impression Materials**.



Call for the latest LVI Promotions **877-532-2123**

Kettenbach has become one of the most modern and advanced dental companies in the world. As a manufacturing leader, Kettenbach develops impression systems which are innovative and simply intelligent. Our A-silicones are known worldwide to be predictable and accurate. As a direct supplier, we give you the chance to use our products without any additional distributor cost, allowing us to bring great quality and precision to your office. For more information, please visit www.kettenbach.com or call 877-532-2123.



ask
Heidi



Q

Dear Heidi,

My wife snores! She says that she doesn't...but, how does she know? She's asleep! I am up half the night nudging her and telling her to turn to her side. Everyone keeps telling me this could be a serious medical condition. Is snoring really that big of a deal?

Sincerely, your sleep deprived reader,
Bob
Omaha, NE

A

Dear Bob,

Although your letter made me giggle a bit...I want you to know that YES, snoring IS a big deal. It could be a sign of Sleep Apnea. Sleep Apnea means to stop breathing during sleep. This is very serious indeed! When someone snores, it could involve a physical obstruction of the upper airway and this would then be what we call Sleep Disordered Breathing (SDB). Sleep apnea is very serious. Not only can it lead to hypertension, cardiovascular events, GERD, and diabetes, it increases the risk of early death.

You should encourage your wife to have a medical and a dental exam by doctors who each deal with this disorder. You should also have Obstructive Sleep Apnea (OSA) training so that you can help her and your patients in the future. From the dental perspective, a custom fitted oral appliance (such as the LVI Somnodent) can be fabricated. This appliance is worn during sleep to stop the jaw from falling back. This helps to keep the airway open. In severe cases a patient may need to be treated by CPAP in addition to the LVI Somnodent.

I hope you will encourage your wife to have this checked out. Not only will you add years to her life...but yours as well!

Heidi

A blue square icon containing a white question mark.

Dear Heidi,

I have suffered from migraine headaches for years...and I don't know where to turn. I have been treated by every doctor imaginable and besides placing me on medications no one has been able to help me. Tumor has been ruled out as well. I am miserable and it seems I'm out of my office more than I am in it. Can my bite be the issue?

Chandra
Dallas, TX

A red square icon containing a white letter 'A'.

Chandra,

I am so glad that you wrote to me. As a past migraine sufferer, I feel your pain...LITERALLY! My heart goes out to you, as I know firsthand how debilitating migraine headaches can be. I suffered from migraines since the age of 13. As a young dentist my situation worsened after I was equilibrated into a CR position that retruded my mandible. After that I suffered daily headaches and weekly migraines that kept me out of the office and in the darkest room of my home (my closet!) When I learned about NM Dentistry I had my bite checked and the findings were amazing! I was only 1mm retruded and had many functional interferences. The EMG's of my muscles confirmed hypertonicity in my current position. My anterior temporalis muscles were off the charts! As you know this muscle retrudes and elevates the mandible and is innervated by the Trigeminal Nerve. This muscle plays a big role in headaches. We TENSEd me and coronoplastied my natural teeth to the Neuromuscular position...a place where my muscles are comfortable and are hypotonic. Because my teeth are my hard tissue stops, the coronoplasty a position in which my muscles are comfortable...and because of this I have not had a single migraine in over 10 years! That is the power of NM Dentistry.

If you have searched all other avenues without relief...you should really look at your teeth/bite to see if that is the culprit. You are not alone. More than 30 Million Americans suffer from migraines. Women are affected 3x more often than men.

With NM dentistry we relax the muscles with a TENS machine to achieve physiologic rest. After TENS these muscles are now Non-Pathologic. The muscles associated with both the Trigeminal and the Facial Nerves are all relaxed via TENS. Then we build the bite to where these muscles are comfortable. By decreasing the noxious stimulus of these muscles to the Trigeminal Complex...we can get rid of migraine. By the way, I have helped every patient that has presented to me with symptoms of migraine. How powerful is that?

Continued on page 16

Continued from page 15

Your first step is to come to LVI's Core I program and start learning this yourself. Your second step is to become a patient yourself so that you can be cured of this pain. By learning this type of dentistry you will be helping so many of your patients and you will also better the quality of your life. You would be TENSEd and a NM bite would be taken and an Orthotic (a mandibular repositioning appliance) would be fabricated. This is the first step to help diagnose if your teeth are the reason for your migraines. I'd put money on the fact that they are!!

I think your health may see a turnaround soon!

Heidi

Dear Heidi,

I am not sure what is happening... but man, I am having a lot of Class V restorations fail. They are popping out and I am not sure what I am doing wrong. Should I switch to a better bonding agent or restorative material?

Thanks for your insight,
Chris
Arlington, VA

Dear Chris,

I am assuming the Class V restorations you are filling are abfraction areas. Abfractions are largely caused by flexural forces. The weakest part of the tooth is where the enamel ends and the cementum begins. If occlusal forces are not down the long access of the tooth, this causes flex in this area. You probably noticed a V or C shaped notch where this occurs. The enamel rods have broken down at the location.

You are doing the right thing by placing a filling in this area. There is NOT a problem with your bonding material or your technique. The problem lies in the occlusion. As a NM dentist, I adjust the bite in function trying to get those forces down the long access of the tooth. Achieving correct centrics is very important on opening and closing. Getting rid of chewing interferences is equally important to attain a balanced bite free of interferences. These interferences are the cause of the abfraction areas. Adjusting the 'chewing cycle' correctly will assure long-lasting restorations in these areas for you.

If you are unsure how to adjust the bite in these ways, please join us at LVI in Core I where we discuss these techniques in depth.

Hope this helped to explain what is really happening with your fillings,

Heidi

LVI can show you how to stay ahead of the curve
empower YOUR PRACTICE

invest
your time

IN YOUR FUTURE WITH CONTINUED EDUCATION
 Discover a path that leads your practice to greater competitive power in the current marketplace. LVI will teach you techniques and procedures that will dramatically enhance the lives of you and your patients.

receive
education

CE CREDITS & COURSE INFORMATION

- Understand the impact of neuromuscular dentistry in the aesthetic practice.
- Discuss the parameters for use of transcutaneous electrical neural stimulation (TENS).
- Learn the basics behind taking a TENS Bite.
- Understand occlusion from a neuromuscular perspective.
- Identify appropriate procedures for smile design and when to use them.
- Define the options for porcelain restorations and the preparation and temporization necessary to accomplish the restoration.
- Implement the latest cementation and anesthetic techniques for better efficiency when delivering a large, aesthetic case.
- Understand the best procedures for diagnosis and treatment planning and better communication with the patient.
- Two day session provides 13 CE hours.

save
your money

REGISTER EARLY AND SAVE ON TUITION FEES

With Regional Events throughout the nation and \$100 savings when you register early for two day sessions, LVI makes it easy and affordable for you to continue your dental education.

register

VISIT WWW.LVIREGIONALEVENTS.COM
 OR CALL 888.584.3237 FOR MORE INFO

2 DAY SESSIONS: Dallas, TX April 27-28 // Sarasota, FL June 8-9
 Hilton Head, NC August 10-11 // Boston, MA August 24-25



LVI Regional Event

SPONSORED BY **MICRODENTAL**
 LABORATORIES

ADA CERP® | Continuing Education
 Recognition Program

LVI Global is an ADA CERP Recognized Provider. ADA CERP is a service of the American Dental Association to assist dental professionals in identifying quality providers of continuing dental education. ADA CERP does not approve or endorse individual courses or instructors, nor does it imply acceptance of credit hours by boards of dentistry. Concerns or complaints about a CE provider may be directed to the provider or to ADA CERP at www.ada.org/cerp.



Academy of General Dentistry
 Approved PACE Program Provider
 FAGD/MAGD Credit
 11/1/2010 to 12/31/2013

Educated Team = Educated Patients



Minette Galura- Boquiren

Has this ever happened to you? Your doctor just completed an exam and explained in detail the treatment that is needed because they have a poor bite. However, as soon as your doctor walks out of the room, the patient turns to you and says, "What do I need again?" The TEAM is the link between the doctor and patient; we are the ones that make things happen!

Recognizing the musculoskeletal signs and symptoms is the first step. EVERY team member should be able to comfortably identify the intra-oral and extra-oral signs in order to correlate them with the patient's symptoms. Having a thorough understanding of the signs and symptoms allows us to effectively communicate with our patients in terms that they can understand. In addition, the acquisition of good diagnostic data: photos, radiographs/CTs, and models, help the patient further comprehend the treatment and enable them to co-diagnose with the doctor. Once the patient gets "it", it's our job to make sure it gets done!

I remember how daunting it seemed at first; like it was going to be so hard to be able to do everything that is needed in a Neuromuscular office. But in many ways it isn't different at all and in the end, it is much easier when we start with comprehensive care in the first

place. As usual, the neuromuscular-based appointment is made and the recordkeeping is in order: consents signed, charts documented, payment plan in place. We set up the operatory while planning ahead for what we need for materials in order to minimize wait time for the patient and the doctor. We provide efficient assistance





“No matter what we do, the Team’s job is to support the doctor in providing the best care and treatment possible for the patient.”

during the procedure in a number of ways, whether it is palpating the muscles for accurate placement of the TENS pads, to running the computerized K7 with ease, to taking the ideal H.I.P. impression on the first try, or simply observing the patient while the doctor shoots

the bite to ensure that they remain in good posture. We also aid our labs by providing them with accurate impressions and complete lab prescriptions with the bite details so we don’t “lose the bite.”

In my years of experience working chairside in the LVI faculty practice, directing the smooth running of our hands-on clinics, and helping to teach in our team programs here at LVI, my observations have been this: the



more the team members know, the more they help to elevate your practice to another level. Education is KEY! Our programs are designed keeping this in mind. When a doctor takes a program at LVI, there is a team program that coincides. Knowledge is power and I encourage every team member to take it to the next level!

No matter what we do, the Team’s job is to support the doctor in providing the best care and treatment possible for the patient. When all of this happens seamlessly, the patient is comfortable and relaxed during their visit. They may still turn to you for a few answers ...however, they also turn to you for a big “Thank You” as well!



Temporomandibular Disorders: *A Position Paper of the International College of Cranio-Mandibular Orthopedics (ICCMO)*

*“Measure what is measurable
and what is not measurable,
make measurable.”*

Galileo Galilei

This position paper is endorsed by the Board of Regents of the International College of Cranio-Mandibular Orthopedics, 2011.

ABSTRACT: Purpose: Two principal schools of thought regarding the etiology and optimal treatment of temporomandibular disorders exist; one physical/functional, the other biopsychosocial. This position paper establishes the scientific basis for the physical/functional. The ICCMO Position: Temporomandibular disorders (TMD) comprise a group of musculoskeletal disorders, affecting alterations in the structure and/or function of the temporomandibular joints (TMJ), masticatory muscles, dentition and supporting structures. The initial TMD diagnosis is based on history, clinical examination and imaging, if indicated. Diagnosis is greatly enhanced with physiologic measurement devices, providing objective measurements of the functional status of the masticatory system: TMJs, muscles and dental occlusion. The American Alliance of TMD organizations represent thousands of clinicians involved in the treatment of TMD. The ten basic principles of the Alliance include the following statement: Dental occlusion may have a significant role in TMD; as a cause, precipitant and /or perpetuating factor. Therefore, it can be stated that the overwhelming majority of dentists treating TMD believe dental occlusion plays a major role in predisposition, precipitation and perpetuation. While our membership believes that occlusal treatments most frequently resolve TMD, it is recognized that TMD can be multi faceted and may exist with co-morbid physical or emotional factors that may require therapy by appropriate providers. The International College of Cranio-Mandibular Orthopedics (ICCMO), composed of academic and clinical dentists, believes that TMD has a primary physical/functional basis. Initial conservative and reversible TMD treatment employing a therapeutic neuromuscular orthosis that incorporates relaxed, healthy masticatory muscle function and a stable occlusion is most often successful. This is accomplished using objective measurement technologies and ultra low frequency transcutaneous electrical neural stimulation (TENS). Conclusion: Extensive literature substantiates the scientific validity of the physical/functional basis of TMD, efficacy of measurement devices and TENS and their use as aids in diagnosis and in establishing a therapeutic neuromuscular dental occlusion. Clinical Implications: A scientifically valid basis for TMD diagnosis and treatment is presented aiding in therapy.

Introduction

The International College of Cranio- Mandibular Orthopedics (ICCMO) was founded in 1979 as an independent dental organization to encourage Research, improve clinical practice and education related to objective measurements of the physiology of the stomatognathic system. Studies by Dr. Bernard Jankelson of the physiology of human dental occlusion, published in 1955,¹ resulted in recognition of the scientific need to quantify the function of the masticatory system. These studies were a driving force in the development, and then introduction, of a physiologically based, objectively measured concept of dental occlusion, called neuromuscular occlusion. Dr. Jankelson's studies of the physiology of human dental occlusion concept he introduced in 1973. Clinically usable devices to measure the function of the components of the masticatory system, the TMJ, muscles and dental occlusion were subsequently invented.^{2,4} Objective measurements of masticatory function and dental occlusion, established the scientific validity of the neuromuscular occlusion concept and its clinical utility.

Like other medical disciplines responsible for diagnosis and treatment of musculoskeletal disorders, the use of objective measurement facilitates differential diagnosis and results in improved treatment outcomes for multi-etiological conditions. Hence, these modalities are tools for diagnosis and treatment of TMD.

ICCMO fosters neuromuscular concepts and practices to alleviate painful conditions related to malocclusion, mandibular, head and neck musculoskeletal dysfunction, including temporomandibular disorders. Members are in both clinical practice and academic institutions, with sections in the USA, Canada, Japan, Italy, Germany, France and South America.

ICCMO members recognize that temporomandibular disorders (TMD) most commonly have a physical/physiological basis with dental malocclusion as a major etiologic agent. They employ neuromuscular occlusal therapies as primary modalities to improve muscle and joint function, utilizing objective measurement data to optimize treatment outcome. These clinical modalities are applied to the treatment of patients with TMD and others who require significant alteration or restoration to a physiological dental occlusion.

II. Temporomandibular Disorders

Temporomandibular disorders (TMD) comprise a group of musculoskeletal disorders that affect alterations in the structure and/or function of one or more of the following: temporomandibular joints (TMJ), masticatory muscles, the dentition and its supporting structures, and the complex neuromuscular system attached thereto. TMD can coexist with other musculoskeletal disorders within the head and neck area. Each TMD patient has a unique composite of different elements, which can involve the TM joint and masticatory muscle systems, often with the pain and dysfunction of physical causes leading to manifestation of psychological stress.

Signs and symptoms determined upon clinical examination are varied and their prevalences have been the subject of extensive research published in the medical and dental literature. In a classical article published in 1934, Costen, an otolaryngologist, observed that posterior condylar displacement in the TM joint created by the dental malocclusion was the cause of otological symptoms in a group of his patients. Costen inserted a dental device and the symptoms were resolved.^{5,6} In a 2007 study performed on 4,528 TMD patients, certain signs and symptoms were found present in extremely large percentages, which helped in the characterization of the TMD patient. In that study, symptoms most commonly reported included: pain 96%, headache 79%, TM joint discomfort or dysfunction 75%, and ear discomfort or dysfunction 82%. The most prevalent examination findings were tenderness to palpation of the lateral and/or medial pterygoid muscles 85% and TM joint tenderness to palpation 62%.⁷ In the medical literature related to TMD, the most commonly reported symptoms are headache and otolaryngological.⁸⁻¹⁰

III. The Role of Dental Occlusion in TMD

Dental occlusion is the cornerstone of stability of the craniomandibular system, comprised of dentition, masticatory muscles and the TM joints. Malocclusion is a destabilizing factor, representing a major predisposing condition for TMD. A number of studies have substantiated an association between dental occlusion and TMD. These studies have documented the role of occlusion as a predisposing, initiating and/or perpetuating factor in the etiology of TMD.¹¹⁻²⁴

In other studies that investigated the cause-effect relationship, the authors experimentally induced TMD in asymptomatic subjects by introducing occlusal interferences into healthy subjects and studied the development of signs and symptoms of TMD. Changes in subjective symptoms and clinical indicators of dysfunction were recorded.²⁵⁻
³⁴ Asymptomatic subjects in all of these studies developed signs and symptoms of TMD, some after only a few hours. According to De Boever, et al.²⁷ who performed a scientific review of the literature on the relationship between occlusion and TMD, “These studies have shown that artificially introduced occlusal interferences can provoke immediate responses in the contraction pattern of jaw muscles and they may induce jaw muscle hyperactivity and pain in some subjects.”

In a three-part study conducted at Karolinska Institute, Riise and Sheikholeslam^{28,30} investigated the influence of an intercuspal occlusal interference that was introduced in 11 healthy subjects with no signs and symptoms of functional disorders. According to this study, in less than 12 hours following the insertion of the interfering amalgam filling, signs and symptoms of functional disorders had developed in eight subjects, accompanied by an increase in the EMG postural activity of the anterior temporalis and masseter muscles. The subjects complained of pain, tenderness and fatigue in their facial muscles. The authors concluded that “Within a week after the occlusal interference was removed, the symptoms gradually subsided... and postural EMG activity had returned almost to its original pattern in all subjects.”

In a randomized double-blind study at University of Turku in Finland, Le Bell, et al.³¹⁻³³ conducted their study on two groups of subjects, all women, that consisted of 26 healthy subjects, and a matched group of 21 subjects with a prior history of TMD who were successfully treated. Each group was randomly divided into two groups of placebo and true interference groups. Experimental occlusal interference was introduced in the true interference groups and simulated in the placebo groups. The investigators monitored the clinical signs of subjects in the resulting four groups for two weeks. Additionally, all subjects rated the intensity of their symptoms on a scale relative to their experience of TMD pain and discomfort. The authors concluded, “subjects with a TMD history and true interference showed a significant increase in clinical signs and

reported stronger symptoms than subjects with no TMD history and placebo interferences.”

These studies demonstrate the presence of several factors when an occlusal interference is introduced. These include the effect of the interference on muscles and joints, the inherent adaptive capacity of the subject, and the influence of suggestion (placebo effect). The results clearly substantiate the role of occlusion in the onset and perpetuation of TMD and a return to normal masticatory function when occlusal harmony is restored.

It is commonly agreed, among dentists who treat patients with TMD, that conservative, reversible therapies should be employed, whenever possible, in the initial phase of treatment. Several studies have concluded that TMD patients experience the greatest clinical success after receiving treatments that involve restoration of optimum function of the mandible, muscles and TM joints, through use of intraoral orthotic appliances of various designs.³⁵⁻⁴¹ The neuromuscular occlusion orthosis recommended by ICCMO is one form of conservative treatment. Some patients, after undergoing successful initial reversible forms of therapy, do not require long-term occlusal stabilization treatment, while others do require long-term continued maintenance of a therapeutic occlusal position to perpetuate initially affected resolution of TMD. The long-term treatment may involve permanent alteration of the occlusal relationship or continued use of precision orthoses. A small number of patients actually require TM joint surgery to treat dysfunctional joints.

IV. Neuromuscular Occlusion

Neuromuscular occlusion is in harmony with relaxed, healthy muscles and properly functioning temporomandibular joints. It is a stable maxillo-mandibular position of dental occlusion arrived at by isotonic contraction of relaxed masticatory muscles, achieved by stimulation of those muscles on a trajectory (arc) beginning at a muscularly rested mandibular position.³⁹ Healthy temporomandibular joint (TMJ) function must be accompanied by a stable dental occlusion, freely entered and exited without interferences, dictated by and directed by healthy relaxed masticatory muscles for long-term stability of all of the interrelated structures.

Joints do not initiate or dictate function; they permit function and adapt to functional demands. Healthy

What does your **future hold?**

Explore your options...

Modern Advances, Techniques and Procedures designed to dramatically enhance the lives of you and your patients!

**Contact Us
for our
Fall Schedule**

Invest in yourself, your practice and your future by exploring “The Future of Dentistry” with Aurum Ceramic and LVI Global.

Learn, through lecture and discussion:

- Best procedures for diagnosis and treatment planning.
- Exciting options for smile design, restoration selection, preparation, temporization and cementation.
- Improved patient communication.
- Proven new concepts in practice marketing.

For more information or courses in your area, check out “Upcoming Courses” off the NEWS & EVENTS Menu at www.aurumgroup.com OR contact Aurum Ceramic Dental Laboratories Continuing Education Department at

**1-800-363-3989 or
email: ce@aurumgroup.com**

PRESENTED BY



TM joint function is not primary, but secondary to a physiological dental occlusion. Form follows function: the shape of hard structures results from the function which they are required to perform.⁴⁰ To protect the hard structures (joints, alveolar bones), healthy function must be provided to the soft tissues (muscles, periodontium and ligaments). Hence, it is valuable to analyze function before form to understand how and why anatomical form was changed. For example, it is valuable to analyze the genesis of the severe attrition seen on incisor teeth prior to treatment planning for porcelain laminate veneers, or the same conditions untreated can cause failure of the new restorations. The concept of a neuromuscular dental occlusion has not changed since its introduction in 1973; only the technology used to establish this therapeutic occlusion has been developed and refined.³

V. Technologies Used in Neuromuscular Dentistry

It is an accepted physiological axiom that muscles function optimally from their full resting length: a rested state.⁴¹ Implementation of the recognition of the essential role of relaxed masticatory muscles as a prerequisite for the establishment of an ergonomic, optimally physiologic occlusion was the impetus for the development of an instrument capable of affecting true physiological masticatory muscle relaxation. The clinical device developed to relax mandibular elevator and depressor muscles is a neuromuscular stimulator (TENS device) that delivers an intermittent minute, low voltage, low amperage, fixed rate neural stimulus simultaneously to all of the masticatory muscles through the mandibular division of the trigeminal nerve applied over the mandibular coronoid notch.⁴²⁻⁴⁴ The stimulator used is similar to other medical nerve mediated ultra-low frequency TENS devices used to affect relaxation of muscles. In the case of TMD; the mandibular elevator and depressor muscles are the stimulated muscles.⁴⁵⁻⁵¹

Proper diagnosis of any medical/ dental condition is made by the treating doctor and begins with obtaining a history of the illness and performing a comprehensive clinical examination of the affected area, employing imaging studies when indicated. The diagnostic process and treatment plan are greatly enhanced using technologies that can scrutinize the anatomic and functional components of the masticatory system, providing reliable and precise objective measurement data. Because of the diversity of structures involved and variability in chronicity

and intensity of TMD presentations between patients, there can be no single diagnostic test with an acceptable level of “specificity” to rule TMD in or out. In medicine, there are many devices considered valuable as diagnostic aids, such as radiographs, MRI, and cardiac stress tests that are not free-standing diagnostic devices. Sometimes, more than one device is used to obtain a proper diagnosis.

Within the past four decades, three computerized measurement devices have been developed and refined to record and analyze, with high degrees of precision, masticatory muscle function (EMG), mandibular movements (CMS), TMJ joint sounds (ESG), and dental occlusion as dynamic phenomena.

Surface Electromyography (EMG) is a well-accepted modality with which to evaluate muscle function. A significant body of the scientific literature published in peer-reviewed journals over the past 50 years has concluded that the TMD patient population has an elevated resting EMG muscle activity and weak or asymmetrical functional EMG muscle activity.⁵²⁻⁹⁶ EMG measures electrical activity in masticatory muscles at rest and in function. This measured activity aids in identification of mandibular rest position as a reference for the selection of the neuromuscular occlusion position, as well as evaluation of the quality of the dental occlusion through the analysis of patterns of muscle motor unit recruitment. Numerous studies have substantiated the reliability and reproducibility of surface electromyography in the evaluation of the status of the masticatory muscles.⁹⁷⁻¹⁰⁸ While “normal or physiological values” for electromyographic (EMG) have been published, because morphologic variations from patient to patient can affect EMG readings, EMG data is utilized to compare electrical activity in selected masticatory muscles before and after treatment for a given patient. In research studies, collective data for a group of subjects are similarly compared. The combination of surface electromyography of masticatory muscles and electronic jaw tracking is a clinically useful and objective method of quantifying the physical components of temporomandibular disorders in patients screened for treatment.¹⁰⁹⁻¹²⁰

Computerized Mandibular Scans (CMS) measure and record mandibular ranges of motion, direction, velocity and fluidity of jaw movements, rest position of the mandible and dental occlusion, both natural and therapeutic. Electrosonography (ESG) records and provides spectral analysis of TM joint sounds,

The Evolution of Floss

The Easy and More Effective Way to Floss!™

New clinical research confirms the Waterpik® Water Flosser is **significantly more effective than both String Floss and Sonicare® Air Floss** for reducing gingivitis. And all Water Pik clinical research is conducted by independent universities and research facilities, and is **published in peer reviewed journals**.

Join the evolution and recommend the Waterpik® Water Flosser for all of your patients who don't like to floss.



Plaque Removal:
99.9%
From Treated Areas¹

Gingivitis Reduction:
50%
More Effective vs. String Floss²

Gingivitis Reduction:
80%
More Effective vs. Sonicare® Air Floss³

1. Gorur A et al. Compend Contin Ed Dent. 2009; 30 (Suppl 1):1 - 6.
 2. Barnes CM et al. Journal of Clinical Dentistry, 2005; 16(3):71-77.
 3. Sharma NC et al. Journal of Clinical Dentistry, 2012; 23: In Press.
- For research abstracts go to Waterpik.com

waterpik®
waterflosser®



identifying their magnitude and specific frequencies produced by mandibular movements during mouth opening and closing with greater precision than stethoscopic auscultation.¹²¹⁻¹²⁴

These three technologies are not free-standing diagnostic devices; they are precision objective measurement instruments, which aid the dentist in establishing a diagnosis. These devices underwent the review processes of the US FDA in 1997 and 1998,^{125,126} and the ADA Council on Scientific Affairs in 1986 and 1993,^{127,128} and have been recognized as safe and effective aids in the diagnosis and treatment of patients with temporomandibular disorders.

According to the ADA's Council on Scientific Affairs,^{129,130} "Surface electromyography, or EMG, is used in dentistry to assess the status of the muscles of mastication.¹³¹ It allows the clinician to assess the resting activity of muscles and determine if muscle spasms are present.^{132,133} In particular, EMG instruments measure static and functional muscle activity, including postural hypertonicity and continuous muscle contraction.¹³³ Evaluation of muscle activity is included among the diagnostic criteria for TMD as given in the ADA Council's Guidelines.... Muscle spasm is included in the counsel's classification system (Section 11.8.3 in the Appendix), and among the diagnostic criteria is continuous muscle contraction at rest. Surface electromyography is one method that can measure such muscle hyperactivity... There is considerable agreement among both clinicians and researchers that masticatory muscle activity is increased in symptomatic patients compared to normal subjects, and electromyography is one tool that can be used to study such differences."¹³⁴ Therefore, EMG devices "were found to meet the [ADA] Council's Guidelines for Instruments as Aids in the Diagnosis of Temporomandibular Disorders."¹³⁰

Neuromuscular measurement devices objectively document patient status, create objective milestones in planning treatment, and document patients' response to treatment.¹³⁵⁻¹⁵² The three devices, computerized jaw tracking, electromyography and electrosonography, provide objective documentation of the pretreatment status of patients with regard to mandibular and masticatory muscle function and permit evaluation of treatment outcomes.

Together with these measurement devices, Transcutaneous Electrical Neural Stimulation (TENS)

is an active therapeutic device that affects relaxation of masticatory and mandibular postural muscles by use of low frequency, low current stimulation of the mandibular division of the trigeminal nerve (CN V) and a branch of the superficial facial nerve (CN VII).⁴²⁻⁴⁵ It is used during the treatment to achieve true rest position of the mandible and a therapeutic neuromuscular occlusal position.¹⁵³⁻¹⁶¹ Thereafter, TENS is employed as an aide in performing occlusal adjustments of the anatomical surface of the neuromuscular TMD orthosis.

Without objective measurement of function, treatment planning and outcome evaluation are subjective and may be imprecise and possibly inaccurate.^{162,163} *With objective measurement*, treatment planning, as well as treatment outcome, whether successful or not, can be scrutinized and evaluated. Treatment can be modified, continued or discontinued, based upon precise objective measurements together with a patient's needs and desires; rather than relying only on subjective evaluations of success by the patient and dentist.

VI. Conclusion

The overwhelming majority of dentists worldwide, treating thousands of patients annually, and whose patients had not previously experienced resolution of their painful and/or dysfunctional symptoms, support the conclusions reached by a large number of studies that TMD is a physical/functional disorder most often resulting from the mal-relationship among the dental occlusion, masticatory muscles, and TM joint function.^{11-34,39,164} They find that their patients are most often conservatively and successfully treatable initially with reversible occlusal orthosis therapy. Members of ICCMO adhere to this principal and treat to establish a healthy craniomandibular relationship through the use of a physiologically balanced neuromuscular occlusion that is in harmony with relaxed, healthy masticatory muscles with improved function and properly functioning TM joints. This achieves a stable, physiologically sound dental and craniomandibular position that does not cause noxious neural input to the central nervous system with resultant adaptive/accommodative function and behavior. In addition to its use in the treatment of patients with TMD, the neuromuscular occlusal philosophy can be successfully applied to all forms of dental treatment that involve major alteration of dental occlusion, including orthodontics, full arch or full mouth reconstruction and complete dentures.

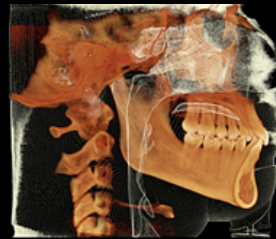
Imaging Systems, Inc.

www.goodxrays.com

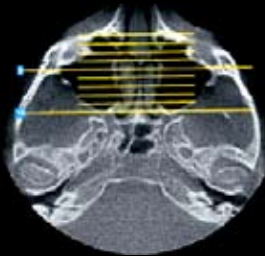
800-628-1302

Introducing the **NewTom VGi**

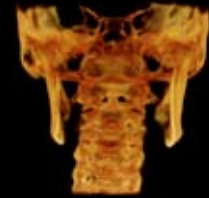Volumetric CBCT 3D Scanner



Volumetric
Airway



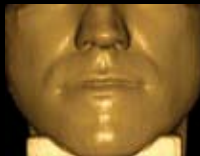Paranasal Sinuses



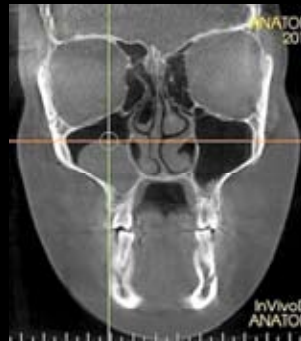PA Cervical Spine



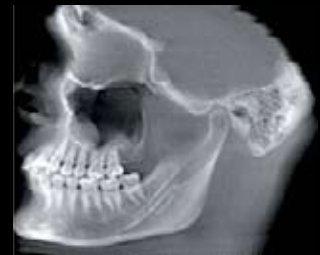Reduced Exposure!



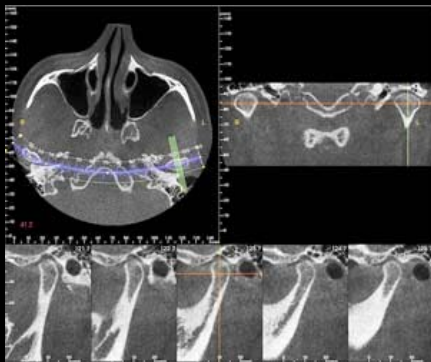
Soft Tissue
Filters



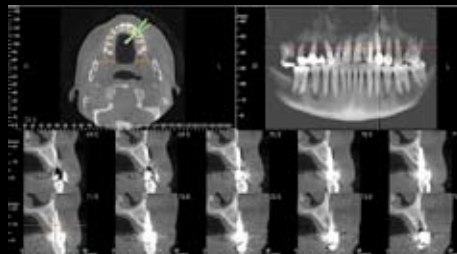
Maxillary Sinuses



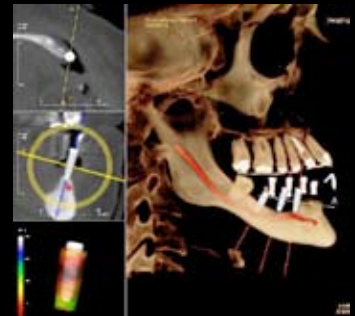
TMJ's, Maxillary Sinus
Pseudocysts



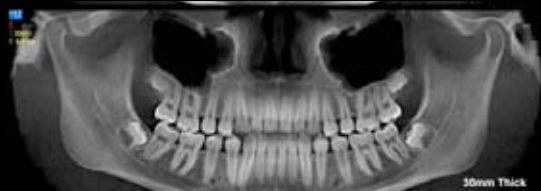TMJ's, Deviated Septums



Implants



A virtually
unlimited number
of images *from a
single scan!*



3D Panoramics



Dick Greenan

"Only the very finest in Cone Beam CT and education!"
"The NewTom VGi was well worth the wait!"

For more information: Call 800-628-1302
or
dick@goodxrays.com



Successful treatment of temporomandibular disorders using neuromuscular occlusion techniques is directed towards elimination of the cause of the disease, not just symptom relief. If the cause is not successfully identified and treated, the acute physical/physiological form of TMD may unfortunately degenerate into a chronic pain condition, rarely cured, and at best, attempted to be managed with pharmacologic and other medical/behavioral therapies. Such symptom- only oriented treatment can adversely affect the patients' ability to work or have normal social interactions, resulting in an overall reduction in quality of life. Published research data demonstrate that the establishment of a neuromuscular therapeutic occlusion provides improved mandibular and masticatory function in a large group of TMD patients with notably significant reduction or resolution of symptoms.^{39,152}

The International College of Cranio-Mandibular Orthopedics supports the consensus among its members and thousands of neuromuscular dentists worldwide that TMD has a primary physical/

functional component that is most often successfully treated with neuromuscular dental occlusion therapy, based on objective measurements.

Dr. Barry Cooper received his D.D.S. degree in 1963 from Columbia University School of Dental and Oral Surgery. He is currently a clinical professor, Division of Translational Oral Biology of the State University of New York (SUNY) Stony Brook School of Dental Medicine. Dr. Cooper has held faculty positions at Columbia University School of Dental and Oral Surgery, New York Medical College, and Temple University School of Dentistry. He is past international president of the International College of Cranio-Mandibular Orthopedics (ICCMO). Dr. Cooper maintains a private practice in Hewlett and Manhattan, New York, limited to the treatment of patients with temporomandibular disorders.

Barry C. Cooper, D.D.S.
Lawrence, New York
tmjbcoper@aol.com

References

- Jankelson B: Physiology of human dental occlusion. J Am Dent Assoc 1955; 50:664-680.
- Jankelson B, Swain C: Kinesioelectric instrumentation: a new technology. J Am Dent Assoc 1975; 90(4):834-840.
- Jankelson B: Neuromuscular aspects of occlusion: effects of occlusal position on the physiology and dysfunction on the mandibular musculature. Dent Clin North Am 1979; 23:157-168.
- Jankelson B: Measurement accuracy of the mandibular kinesiograph: a computerized study. J Prosthet Dent 1980; 44(6):656-666.
- Costen JB: A syndrome of ear and sinus symptoms dependent upon disturbed function of the temporomandibular joint. Ann Otol Rhinol Laryngol 1934; 43:1-5.
- Costen J: Neuralgia and ear symptoms associated with disturbed function of the temporomandibular joint. JAMA 1936; 107:252-256.
- Cooper BC, Kleinberg I: Examination of a large patient population for presence of symptoms and signs of temporomandibular disorders. J Craniomandib Pract 2007; 25(2):114-126.
- Cooper BC, Cooper DL: Recognizing otolaryngologic symptoms in patients with temporomandibular disorders. J Craniomandib Pract 1993; 11(4):260-267.
- Tuz H, Onder E, Kinisi R: Prevalence of otologic complaints in patients with temporomandibular disorder. Am J Orthod Dentofac Orthop 2003; 123:620-623.
- Cooper B, Kleinberg I: Relationship of temporomandibular disorders to muscle and tension-type headaches and a neuromuscular orthosis approach to treatment. J Craniomandib Pract 2009 27(2):101-108.
- Kirveskari P, Alanen P, Jämsä T: Association between craniomandibular disorders and occlusal interferences. J Prosthet Dent 1989;
- Kirveskari P, LeBell Y, Salonen M, Forssell H, Grans L: Effect of elimination of occlusal interferences on signs and symptoms of craniomandibular disorder in young adults. J Oral Rehabil 1989; 16 (1):21-26.
- Fushima K, Akimoto S, Takamoto K, Kamei T, Sato S, Suzuki Y: Incidence of temporomandibular joint disorders in patients with malocclusion. Nihon Ago Kansetsu Gakkai Zasshi 1989; 1(1):40-50.
- Raustia AM, Pirttiniemi PM, Pyhtinen J: Correlation of occlusal factors and condyle position asymmetry with signs and symptoms of temporomandibular disorders in young adults. J Craniomandib Pract 1995; 13(3):152-156.
- Raustia AM, Pyhtinen J, Tervonen O: Clinical and MRI findings of the temporomandibular joint in relation to occlusion in young adults. J Craniomandib Pract 1995; 13(2):99-104.
- Liu JK, Tsai MY: Association of functional malocclusion with temporomandibular disorders in orthodontic patients prior to treatment. Funct Orthod 1998; 15(3):17-20.
- Kirveskari P, Jämsä T, Alanen P: Occlusal adjustment and the incidence of demand for temporomandibular disorder treatment. J Prosthet Dent 1998; 79(4):433-438.
- Mao Y, Duan XH: Attitude of Chinese orthodontists towards the relationship between orthodontic treatment and temporomandibular disorders. Int Dent J 2001; 51(4):277-281.
- Sonnenes L, Bakke M, Solow B: Malocclusion traits and symptoms and signs of temporomandibular disorders in children with severe malocclusion. Eur J Orthod 1998; 20(5):543-559.
- Čečić R, Kraljević K, Kraljević S, Badel T, Pandurić J: The correlation between temporomandibular disorders and morphological occlusion. Acta Stomatologica Croatica 2000; 34(1).
- Kirveskari P, Alanen P, Jämsä T: Association between craniomandibular disorders and occlusal interferences in children. J Prosthet Dent 1992; 67(5):692-696.
- Fushima K, Inui M, Sato S: Dental asymmetry in temporomandibular disorders. J Oral Rehabil 1999; 26(9):752-756.
- Klopprogge MJ, van Griethuysen AM: Disturbances in the contraction and co-ordination pattern of the masticatory muscles due to dental restorations. An electromyographic study. J Oral Rehabil 1976 3(3):207-216.
- Beltollahi JM, Mansourian A, Bozorgi Y, Farrokhnia T, Manavi A: Evaluating the most common etiologic factors in patients with temporomandibular disorders: A case control study. J Applied Sciences 2008; 8(24):4702-4705.
- Christensen LV, Rassouli NM: Experimental occlusal interferences. Part I. A review. J Oral Rehabil 1995; 22(7):515-520.
- Randow K, Carlsson K, Edlund J, Öberg T: The effect of an occlusal interference on the masticatory system. An experimental investigation. Odontol Rev 1976; 27(4):245-256.
- De Boever JA, Carlsson GE, Klineberg J: Need for occlusal therapy and prosthodontic treatment in the management of temporomandibular disorders. Part I. Occlusal interferences and occlusal adjustment. J Oral Rehabil 2000; 27(5):367-379.
- Riise C, Sheikholeslam A: The influence of experimental interfering occlusal contacts on postural activity of the anterior temporal and masseter muscles in young adults. J Oral Rehabil 1982; 9:419-425.
- Sheikholeslam A, Riise C: Influence of experimental interfering occlusal contacts on the activity of the anterior temporal and masseter muscles during submaximal and maximal bite in the intercuspation position. J Oral Rehabil 1983; 10:207-214.
- Riise C, Sheikholeslam A: The influence of experimental interfering occlusal contacts on the activity of the anterior temporal and masseter muscles during mastication. J Oral Rehabil 1984; 11:325-333.
- Le Bell Y, Jämsä T, Korri S, Niemi PM, Alanen P: Effect of artificial occlusal interferences depends on previous experience of temporomandibular disorders. Acta Odontol Scand 2002; 60(4):219-222.
- Niemi PM, Jämsä T, Kylmäälä M, Alanen P: Subjective reactions to intervention with artificial interferences in subjects with and without a history of temporomandibular disorders. Acta Odontol Scand 2006; 64(1):59-63.
- Niemi PM, Le Bell Y, Kylmäälä M, Jämsä T, Alanen P: Psychological factors and responses to artificial interferences in subjects with and without a history of temporomandibular disorders. Acta Odontol Scand 2006; 64(5):300-305.
- Li J, Jiang T, Feng H, Wang K, Zhang Z, Ishikawa T: The electromyographic activity of masseter and anterior

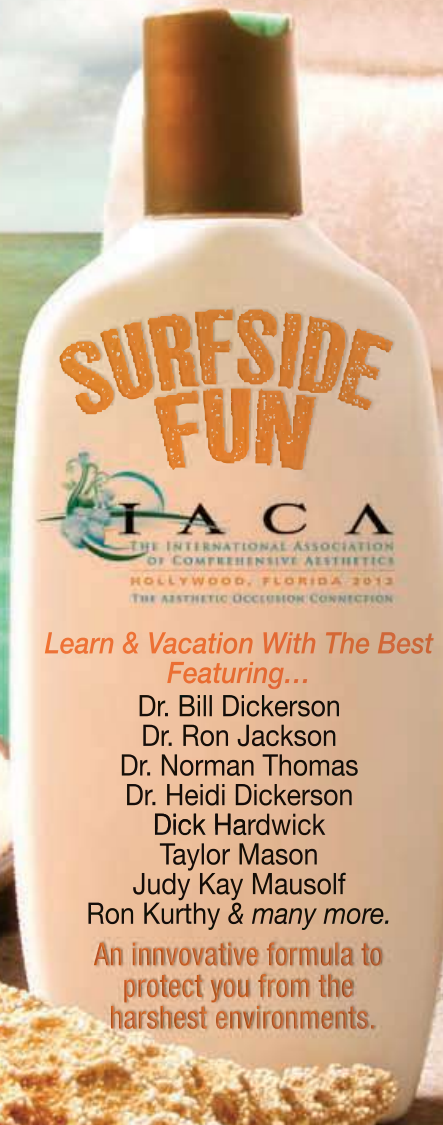
BEACH & LEARN

Combine Learning and Family Time!

Join us surfside for the 2012 IACA Conference,

JULY 26-28, 2012

at the **Westin Diplomat** in Hollywood, Florida.



*Learn & Vacation With The Best
Featuring...*

Dr. Bill Dickerson
Dr. Ron Jackson
Dr. Norman Thomas
Dr. Heidi Dickerson
Dick Hardwick
Taylor Mason
Judy Kay Mausolf
Ron Kurthy & many more.

*An innovative formula to
protect you from the
harshest environments.*



MICRODENTAL
LABORATORIES



Space is limited. Register early at www.theIACA.com or 1.866.NOW.IACA.

- temporalis during orofacial symptoms induced by experimental occlusal highspot. *J Oral Rehabil* 2008; 35(2):79-87.
35. Williamson EH, Rosenzweig BJ: The treatment of temporomandibular disorders through repositioning splint therapy: a follow-up study. *J Craniomandib Pract* 1998; 16(4):222-225.
 36. Lundh H, Westesson P-L, Kopp S, Tillström B: Anterior repositioning splint in the treatment of temporomandibular joints with reciprocal clicking: comparison with a flat occlusal splint and an untreated control group. *Oral Surg Oral Med Oral Pathol* 1985; 60(2):131-136.
 37. Lundh H, Westesson P-L, Jisander S, Eriksson L: Disc-repositioning onlays in the treatment of temporomandibular joint disk displacement: comparison with a flat occlusal splint and with no treatment. *Oral Surg Oral Med Oral Pathol* 1988; 66(2):155-162.
 38. Simmons HC III, Gibbs SJ: Anterior repositioning appliance therapy for TMJ disorders: specific symptoms relieved and relationship to disc status on MRI. *J Craniomandib Pract* 2005; 23(2):89-99.
 39. Cooper B, Kleinberg I: Establishment of a temporomandibular physiological state with neuromuscular orthosis treatment affects reduction of TMD symptoms in 313 patients. *J Craniomandib Pract* 2008; 26(2):104-117.
 40. Moss ML: Functional matrix hypothesis. In: *Vistas in orthodontics*. Kraus B, Riedel R, eds. Philadelphia: Lea & Febiger, 1962.
 41. Guyton AC: *Textbook of medical physiology*, 6th ed. Philadelphia: WB Saunders, 1981:137.
 42. Jankelson B, Swain CW: Physiological aspects of masticatory muscle stimulation: the Myomonitor. *Quintessence Int* 1972; 3:57-62.
 43. Jankelson B, Sparks S, Crane PF, Radke JC: Neural conduction of the Myo-monitor stimulus: a quantitative analysis. *J Prosth Dent* 1975; 34(3):245-253.
 44. Jankelson B, Radke J: The myo-monitor: its use and abuse Parts I and II. *Quintessence International Dent Digest, Special Report* 1601. 1978; 9(2):35-39, 9(3):47-52.
 45. Dixon HH, O'Hara M: Fatigue contracture of skeletal muscles. *J Northwest Med* 1967; 66:813-816.
 46. Dixon HH, O'Hara M: Tension headache. *J Northwest Med* 1967; 66:817-820.
 47. Wessberg GA, Carroll WL, Dinham R, Wolford LM: Transcutaneous electrical stimulation as an adjunct in the management of myofascial pain dysfunction syndrome. *J Prosth Dent* 1981; 45(3): 304-314.
 48. Kawazoe Y, Kotani H, Mitani T, et al.: The slopes of the fatigued muscle voltage tension curves decreased to a greater degree with percutaneous stimulation than with rest alone. *Arch Oral Biol* 1981; 26:796-801.
 49. Bazzotti L: Electromyography tension and frequency spectrum analysis at rest of some masticatory muscles before and after TENS. *Electromyography Clin Neurophysiol* 1997; 37(6):365-378.
 50. Kamyszek G, Ketcham R, Garcia R Jr.: Electromyographic evidence of reduced muscle activity when ULF-TENS is applied to the Vth and VIIIth cranial nerves. *J Craniomandib Pract* 2001; 19(3):162-168.
 51. Elbo OS, Jonas IE, Kappert HF: Transcutaneous electrical nerve stimulation (TENS): its short-term and long-term effects on the masticatory muscles. *J Orofac Orthop* 2006; 61(2):100-111.
 52. Jarabak JR: An electromyographic analysis of muscular and temporomandibular joint disturbances due to imbalances in occlusion. *Angle Orthod* 1956; 26:170-190.
 53. Perry HT: Muscular changes associated with temporomandibular joint dysfunction. *Journal of Am Dent Res* 1957; 54:644-653.
 54. Lous L, Sheikholeslam A, Moller E: Postural activity in subjects with functional disorders of the chewing apparatus. *Scand J Dent Res* 1970; 78:404-410.
 55. Moller E, Sheikholeslam A, Lous L: Deliberate relaxation of the temporal and masseter muscles in subjects with functional disorders of the chewing apparatus. *Scand J Dent Res* 1971; 79:478-482.
 56. Munro RR: Electromyography of the masseter and anterior temporalis muscles in patients with atypical facial pain. *Australian Dent J* 1972:131-139.
 57. Moss JP, Chalmers CF: An electromyographic investigation of patients with a normal jaw relationship and a class III jaw relationship. *Am J Orthod* 1974; 66:538-556.
 58. Yemm R: Neurophysiologic studies of temporomandibular joint dysfunction. *Oral Science Rev* 1976; 7:31-53.
 59. Kotani H, Kawazoe Y, Hamada T, Yamata S: Quantitative electromyographic diagnosis of myofascial pain dysfunction syndrome. *J Prosth Dent* 1980; 43:450-456.
 60. Sheikholeslam A, Moller E, Lous L: Pain, tenderness and strength of human mandibular elevators. *Scand J Dent Res* 1980; 88:60-66.
 61. Sheikholeslam A, Moller E, Lous L: Postural and maximal activity in elevators of mandible before and after treatment of functional disorders. *Scand J Dent Res* 1982; 90:37-46.
 62. Riise C, Sheikholeslam A: The influence of experimental interfering occlusal contacts on the postural activity of the anterior temporal and masseter muscles in young adults. *J Oral Rehabil* 1982; 9:419-425.
 63. Sheikholeslam A, Riise C: Influence of experimental interfering occlusal contacts on the activity of the anterior temporal and masseter muscles during submaximal and maximal bite in the intercuspal position. *J Oral Rehabil* 1983; 10:207-214.
 64. Riise C, Sheikholeslam A: The influence of experimental interfering occlusal contacts on the activity of the anterior temporal and masseter muscles during mastication. *J Oral Rehabil* 1984; 11:325-333.
 65. Moller E, Sheikholeslam A, Lous L: Response of elevator activity during mastication to treatment of functional disorders. *Scand J Dent Res* 1984; 90:37-46.
 66. Keefe FJ, Dolan EA: Correlation of pain behavior and muscle activity in patients with myofascial pain-dysfunction syndrome. *J Craniomandib Disord Facial Oral Pain* 1984; 2:181-184.
 67. Sherman RA: Relationships between jaw pain and jaw muscle contraction level: Underlying factors and treatment effectiveness. *J Prosth Dent* 1985; 54(1):114-118.
 68. Naeije M, Hansson TL: Electromyographic screening of myogenous and arthrogenous TMJ dysfunction patients. *J Oral Rehabil* 1986; 13(5):433-441.
 69. Balciunas BA, Staling LM, Parente FL: Quantitative electromyographic response to therapy for myo-oral facial pain: a pilot study. *J Prosth Dent* 1987; 58(3):366-369.
 70. Burdette BH, Gale EN: The effects of treatment on masticatory muscle activity and mandibular posture in myofascial pain-dysfunction patients. *J Dent Res* 1988; 67(8):1126-1130.
 71. Cram JR, Klemens TM: EMG: Comparisons in craniofacial muscles following therapy for head and neck pain. *Med Electr* 1988:106-110.
 72. Gervais RO, Fitzsimmons GW, Thomas NR: Masseter and temporalis electromyographic activity in asymptomatic, subclinical and temporomandibular joint dysfunction patients. *J Craniomandib Pract* 1989; 7:52-57.
 73. Chong-Shan S, Hui-Yun W: Postural and maximum activity in elevators during mandible pre- and post-occlusal split treatment of temporomandibular joint disturbance syndrome. *J Oral Rehabil* 1989; 16:155-161.
 74. Chong-Shan S, Hui-Yun W: Value of EMG analysis of mandibular elevators in open-close-clench cycle to diagnosing TMJ disturbance syndrome. *J Oral Rehabil* 1989; 16:101-107.
 75. Shi CS: Proportionality of mean voltage of masseter muscle to maximum bite force applied for diagnosing temporomandibular joint disturbance syndrome. *J Prosth Dent* 1989; 62(6):682-684.
 76. Harness DM, Donlon WC, Eversole LR: Comparison of clinical characteristics in myogenic, TMJ internal derangement and atypical facial pain patients. *Clin J Pain* 1990; 6(1):4-17.
 77. Choi J: A study on the effects of maximal voluntary clenching on the tooth contact points and masticatory muscle activities in patients with temporomandibular disorders. *J Craniomandib Disord Facial Oral Pain* 1992; 6:41-46.
 78. Kroon GW, Naeije M: Electromyographic evidence of local muscle fatigue in a subgroup of patients with myogenous craniomandibular disorders. *Arch Oral Biol* 1992; 37(3):215-218.
 79. Visser A, McCarroll RS, Oosting J, Naeije M: Masticatory electromyographic activity in healthy young adults and myogenous craniomandibular disorder patients. *J Oral Rehabil* 1994; 21(1):67-76.
 80. Abeкура H, Kotani H, Tokuyama H, Hamada T: Asymmetry of masticatory muscle activity during intercuspal maximal clenching in healthy subjects and subjects with stomatognathic dysfunction syndrome. *J Oral Rehabil* 1995; 22(9):699-704.
 81. Erlanson PM, Poppen R: Electromyographic biofeedback and rest position training of masticatory muscles in myofascial pain-dysfunction patients. *J Prosth Dent* 1998; 62:335-338.
 82. Liu ZJ, Yamagata K, Kasahara Y, Ito G: Electromyographic examination of jaw muscles in relation to symptoms and occlusion of patients with temporomandibular joint disorders. *J Oral Rehabil* 1999; 26(1):33-47.
 83. Pinho JC, Calkas FM, Mora MJ, Santana-Penin U: Electromyographic activity in patients with temporomandibular disorders. *J Oral Rehabil* 2000; 27(11):985-990.
 84. Alajbeg IZ, Valentic-Peruzovic M, Alajbeg I, Illes D: Influence of occlusal stabilization splint on the asymmetric activity of masticatory muscles in patients with temporomandibular dysfunction. *Coll Antropol* 2003; 27(1):361-371.
 85. Giaros AG, Burton E: Parafunctional clenching, pain, and effort in temporomandibular disorders. *J Behav Med* 2004; 27(1):91-100.
 86. Pallegama RW, Ranasinghe AW, Weerasinghe VS, Sitheque MA: Influence of masticatory muscle pain on electromyographic activities of cervical muscles in patients with myogenous temporomandibular disorders. *J Oral Rehabil* 2004; 31(5):423-429.
 87. Bodéré C, Téa SH, Giroux-Metges MA, Woda A: Activity of masticatory muscles in subjects with different orofacial pain conditions. *Pain* 2005; 116(1-2):33-41.
 88. da Silva MA, Issa JP, Vitti M, da Silva AM, Semprini M, Regalo SC: Electromyographical analysis of the masseter muscle in dentulous and partially toothless patients with temporomandibular joint disorders. *Electromyogr Clin Neurophysiol* 2006; 46(5):263-268.
 89. Tosato Jde P, Caria PH: Electromyographic activity assessment of individuals with and without temporomandibular disorder symptoms. *J Appl Oral Sci* 2007; 15(2):152-155.
 90. Ries LG, Alves MC, Bérzin F: Asymmetric activation of temporalis, masseter, and sternocleidomastoid muscles in temporomandibular disorder patients. *J Craniomandib Pract* 2008; 26(1):59-64.
 91. Tartaglia GM, Moreira Rodrigues da Silva MA, Bottini S, Sforza C, Ferrario VF: Masticatory muscle activity during maximum voluntary clench in different research diagnostic criteria for temporomandibular disorders (RDC/TMD) groups. *Man Ther* 2008; 13(5):434-440.
 92. Bodéré C, Woda A: Effect of a jig on EMG activity in different orofacial pain conditions. *Int J Prosthodont* 2008; 21(3):253-258.
 93. Tecco S, Tetè S, D'Attilio M, Perillo L, Festa F: Surface electromyographic patterns of masticatory, neck, and trunk muscles in temporomandibular joint dysfunction patients undergoing anterior repositioning splint therapy. *Eur J Orthod* 2008; 30(6):592-597.
 94. Santana-Mora, U, Cudeiro J, Mora-Bermudez MJ, Rilo-Pousa B, Ferreira-Pinho JC, Otero-Cepeda JL, Santana-Penin U: Changes in EMG activity during clenching in chronic pain patients with unilateral temporomandibular disorders. *J Electromyography and Kinesiology* 2009; 19(6):e543-549.
 95. Ardizzone I, Celemin A, Aneiros F, del Rio J, Sanchez T, Moreno I: Electromyographic study of activity of the masseter and anterior temporalis muscles in patients with temporomandibular joint (TMJ) dysfunction: comparison with the clinical dysfunction index. *Med Oral Patol Oral Cir Bucal* 2010; 15(1):e14-19.
 96. Botelho AL, Silva BC, Gentil FH, Sforza C, da Silva MA: Immediate effect of the resilient splint evaluated using surface electromyography in patients with TMD. *J Craniomandib Pract* 2010; 28(4):266-273.
 97. Hermens HJ, Boon KL, and Zilvold G: The clinical use of surface EMG. *Medica Physica* 1986; 9:119-130.
 98. Goldensohn E: *Electromyography*. In: *Disorders of the temporomandibular joint*. Lazlo Schwartz, ed. Philadelphia/London: W.B. Saunders Co., 1966:163-176.
 99. Lloyd AJ: Surface electromyography during sustained isometric contractions. *J Applied Physiology* 1971; 30(5):713-719.
 100. Burdette BH, Gale EN: Intersession reliability of surface electromyography. *Journal of Dental Research*, [Abstract No. 1370], Vol 66, 1987.
 101. Christensen LV: Reliability of maximum static work efforts by the human masseter muscle. *Am J Orthod Dentofacial Orthop* 1989; 95(1):42-45.
 102. Burdette BH, Gale EN: Reliability of surface electromyography of the masseteric and anterior temporal areas. *Arch Oral Biol* 1990; 35(9):747-751.
 103. Ferrario VF, Sforza C: Coordinating electromyographic activity of the human masseter and temporalis anterior muscles during mastication. *Eur J Oral Sci* 1996; 104(5-6): 511-517.

MYOTRONICS

46TH Anniversary Seminar
June 29-30, 2012

The Power of Neuromuscular Dentistry

- Achieve predictable results in Aesthetics, Restorative or TMD
- New to NM or Veteran: Practical Information for Everyone
- Bonus: Beautiful Seattle in the Summertime

Featuring physician,
celebrated tenor and
motivational speaker

Ronan Tynan



Academy
of Dental Excellence
PACE
Program Approval for
Continuing Education

Approved PACE Program Provider
PACE/AMGO Oral Approval does not imply
endorsement by a state or provincial board of
dentistry or ASD endorsement.
(878) 1111 to (868) 0119
Provider # 10205



Celebrating 46 Years of Leadership in Neuromuscular Dentistry

800-426-0316 • www.myotronics.com • info@myotronics.com

104. Buxbaum J, Mylinski N, Parente FR: Surface EMG reliability using spectral analysis. *J Oral Rehabil* 1996; 23(11):771-775.
105. Castorfforio T, Icardi K, Torsello F, Deregius A, Debernardi C, Bracco P: Reproducibility of surface EMG in the human masseter and anterior temporalis muscle areas. *J Craniomandib Pract* 2005; 23(2):130-137.
106. Castorfforio T, Icardi K, Becchino B, Merlo E, Debernardi C, Bracco P, Farina D: Reproducibility of surface EMG variables in isometric sub-maximal contractions of jaw elevator muscles. *J Electromyogr Kinesiol* 2006; 16(5):498-505. Epub 2005 Nov 15.
107. Castorfforio T, Bracco P, Farina D: Surface electromyography in the assessment of jaw elevator muscles. *J Oral Rehabil* 2008; 35(8):638-645. Epub 2008 May 9.
108. De Felicio CM, Sidequersky FV, Tartaglia GM, Storza C: Electromyographic standardized indices in healthy Brazilian young adults and data reproducibility. *J Oral Rehabil* 2009; 36(8):577-583. Epub 2009 Jun 22.
109. Pantaleo T, Präyer-Galletti F, Pini-Prato G, Präyer-Galletti S: An electromyographic study in patients with myofascial pain-dysfunction syndrome. *Bulletin Group. Int Rech Stöhler C, Yamada Y, Ash MM: Antagonistic muscle stiffness and associated behavior in the pain dysfunctional state. Helv Odont Acta* 1985; 29:2, also in *Schweiz. Mschr. Zahnmed* 1985; 95:719-726.
111. Stöhler C, Ash MM: Demonstration of chewing motor disorder by recording peripheral correlates of mastication. *J Oral Rehabil* 1985; 12:49-57.
112. Cooper BC, Alleva M, Cooper D, Lucente FE: Myofascial pain dysfunction: analysis of 476 patients. *Laryngoscope* 1986; 96:1099-1106.
113. Nielsen I, Miller AJ: Response patterns of craniomandibular muscles with and without alterations in sensory feedback. *J Prosthet Dent* 1988; 59(3):352-362.
114. Mongini F, Tegia-Valenta G, Conserva E: Habitual mastication in dysfunction: a computer-based analysis. *J Prosthet Dent* 1989; 1:484-494.
115. Williamson EH, Hall JT, Zwemer JD: Swallowing patterns in human subjects with and without temporomandibular dysfunction. *Am J Orthod Dentofac Orthop* 1990; 98:507-511.
116. Nielsen IL, McNeill C, Danzig W, Goldman S, Levy J, Miller AJ: Adaptation of craniofacial muscles in subjects with craniomandibular disorders. *Am J Orthod Dentofac Orthop* 1990; 97(1):20-34.
117. Kuwahara T, Miyauchi S, Maruyama T: Clinical classification of the patterns of mandibular movements during mastication in subjects with TMJ disorders. *Int J Prosthodont* 1992; 5(2):122-129.
118. Tsolka P, Fenion M, McCulloch A, Preiskel H: Controlled clinical, electromyographic and kinesigraphic assessment of craniomandibular disorders in women. *J Orofacial Pain* 1994; 8:80-89.
119. Kuwahara T, Bessette RW, Maruyama T: Chewing pattern analysis in TMD patients with unilateral and bilateral internal derangement. *J Craniomandib Pract* 1995; 13(3):167-172.
120. Cooper BC: The role of bioelectronic instruments in documenting and managing TMD. *New York State Dental Journal* 1995; November:48-53.
121. Heffez L, Blaustein D: Advances in sonography of the temporomandibular joint. *Oral Surg Oral Med Oral Pathol* 1986; 62(5):486-495.
122. Gay T, Bertolami CN, Donoff RB, Keith DA, Kelly JP: The acoustical characteristics of the normal and abnormal temporomandibular joint. *J Oral Maxillofac Surg* 1987; 45(5):397-407.
123. Ishigaki S, Bessette RW, Maruyama T: A clinical study of temporomandibular joint (TMJ) vibrations in TMJ dysfunction patients. *J Craniomandib Pract* 1993; 11(1):7-13; [Discussion, 14].
124. Deng M, Long X, Dong H, Chen Y, Li X: Electrosonographic characteristics of sounds from temporomandibular joint disc replacement. *Int J Oral Maxillofac Surg* 2006; 35(5):456-460.
125. US Food and Drug Administration. Re-review of Devices for Diagnosis and Management of TMJ/TMD, October 20, 1997
126. U.S. Food and Drug Administration: Meeting of the Dental Products Advisory Panel regarding the Classification of Devices for the Treatment and/or Diagnosis of Temporomandibular Joint Dysfunction and/or Orofacial Pain. August 5, 1998.
127. ADA Council on Dental Materials, Instruments and Equipment: Seal of Recognition, January 3, 1986.
128. ADA Council on Dental Materials, Instruments and Equipment: Seal of Acceptance, June 16, 1993.
129. Report on Acceptance of TMD Devices. ADA Council on Scientific Affairs. *J Am Dent Assoc* 1996; 127:1615-1616.
130. Council on Dental Materials: Instruments and Equipment: Acceptance Program Guidelines for Instruments and Aids in the Diagnosis of Temporomandibular Disorders. Chicago American Dental Association, 1991.
131. Dahlstrom L: Electromyographic studies of craniomandibular disorders: a review of the literature. *J Oral Rehabil* 1989; 16:120.
132. Travell JG, Simons DG: Myofascial pain and dysfunction. Baltimore: Williams & Wilkins 1983:169-170.
133. Talley RL, Murphy GJ, Smith SD, Baylin MA, Haden JL: Standards for the history, examination, diagnosis, and treatment of temporomandibular disorders: a position paper. *J Craniomandib Pract* 1990; 8:60-64.
134. McCall WD Jr.: A textbook of occlusion. Carol Stream, IL: Quintessence; 1988.
135. Moller E: Clinical electromyography in dentistry. *Int Dent J* 1969; 19:250-266.
136. Kawazoe Y, Kotani H, Hamada T, Yamada S: Effect of occlusal splints on the electromyographic activities of masseter muscles during maximum clenching in patients with myofascial pain dysfunction syndrome. *J Prosthet Dent* 1980; 43:578-580.
137. Myslinski NR, Buxbaum JD, Parente FJ: The use of electromyography to quantify muscle pain. *Meth and Find Exptl Clin Pharmacol* 1985; 7(10):551-556.
138. Sheikholeslam A, Holmgren K, Riise C: A clinical and electromyographic study of the longterm effects of an occlusal splint on the temporal and masseter muscles in patients with functional disorders and nocturnal bruxism. *J Oral Rehabil* 1986; 13:137-145.
139. Jankelson RR: Analysis of maximal electromyographic activity of the masseter and anterior temporalis muscles in myocentric and habitual centric in temporomandibular joint and musculoskeletal dysfunction. In: *Pathophysiology of head and neck musculoskeletal disorders*. Bergamini M, Präyer Galletti S, eds, Front Oral Physiol, Basel Karger 1990; 7:83-98.
140. Lynn JM: Craniofacial neuromuscular dysfunction vs. function: A comparison study of the condylar position and intra-articular space. In: *Pathophysiology of head and neck musculoskeletal disorders*. Bergamini M, Präyer Galletti S, eds. Front Oral Physiol, Basel Karger 1990; 7:136-143.
141. Coy RE, Flocken JE, Adib F: Musculoskeletal etiology and therapy of craniomandibular pain and dysfunction. *Cranio Clinics Intl* 1991:163-173.
142. Lynn JM, Mazzocco M: Intraoral splint therapy: muscles objectively. *Funct Orthodont* 1991:11-27.
143. Jankelson RR: Validity of surface electromyography as the "gold standard" for measuring muscle postural tonicity in TMD patients. In: *Anthology of craniomandibular orthopedics*. Vol. II, Coy R, ed. International College of Cranio-Mandibular Orthopedics, Seattle WA 1992:103-125.
144. Lynn J, Mazzocco M, Miloser S, Zullo T: Diagnosis and treatment of craniocervical pain and headache based on neuromuscular parameters. *Am J of Pain Mgt* 1992; 2(3):143-151.
145. Hickman DM, Cramer R, Stauber WT: The effect of four jaw relations on electromyographic activity in human masticatory muscles. *Archs Oral Biol* 1993; 38(3):261-264.
146. Bracco P, Deregius A, Piscetta R, Giarretta GA: TMJ clicking: a comparison of clinical examination, sonography, and axiography. *J Craniomandib Pract* 1997; 15(2):121-126.
147. Widmalm DM, Cramer R: The effect of different condylar positions on masticatory muscle electromyographic activity in humans. *Oral Surg Oral Med Oral Pathol Oral Radiol Endod* 1986; 86(1):2-3.
148. Elfving L, Helkimo M, Magnusson T: Prevalence of different temporomandibular joint sounds, with emphasis on disk-displacement, in patients with temporomandibular disorders and controls. *Swed Dent J* 2002; 26(1): 9-19.
149. Widmalm SE, Lee YS, McKay DC: Clinical use of qualitative electromyography in the evaluation of jaw muscle function: a practitioner's guide. *J Craniomandib Pract* 2007; 25:1-11.
150. Hugger G, Hugger S, Schindler H: Surface electromyography of the masticatory muscles for application in dental practice. Current evidence and future developments. *Int J Comput Dent* 2008; 11(2):81-106.
151. Cooper B: The role of bioelectric instrumentation in documenting and managing temporomandibular disorders. *J Am Dent Assoc* 1996; 127:1161-1164.
152. Cooper B: The role of bioelectric instrumentation in the documentation of management of temporomandibular disorders. *Oral Surg Oral Med Oral Pathol Oral Radiol Endod* 1997; 83(1): 91-100. 153. Shpuntoff H, Shpuntoff W: A study of physiological rest position and centric position by electromyography. *J Prosthet Dent* 1956; 6(5):621-628.
154. Choi B: On the mandibular position regulated by Myo-monitor stimulation. *J Japanese Prosthetic Dent* 1973; 17:73-96.
155. Wessberg GA, Epper BN, Elliot AC: Comparison of mandibular rest positions induced by phonetics, transcutaneous electrical stimulation and masticatory electromyography. *J Prosthet Dent* 1983; 49(1):100-105. 156. Williamson E, Marshall D: Myomonitor rest position in the presence and absence of stress. In: *Facial orthopedics and temporomandibular arthrography*. Williamson E, ed. 1986; 3(2):14-17.
157. Konchak P, Thomas N, Lanigan D, Devon R: Freeway space measurement using Mandibular Kinesigraph and EMG before and after TENS. *Angle Orthodontist* 1988; 58(4):343-350.
158. Michelotti A, Farella M, Vollaro S, Martina R: Mandibular rest position and electrical activity of the masticatory muscles. *J Prosthet Dent* 1997; 78:48-53.
159. Jankelson RR: Effect of vertical and horizontal variants on the resting activity of the masticatory muscles. In: *Anthology of craniomandibular orthopedics*. Vol IV, Coy R, ed. International College of Cranio-Mandibular Orthopedics, Seattle WA. 1997: 69-76.
160. Mann A, Miralles R, Cumsille F: Influence of vertical dimension on masseter muscle electromyographic activity in patients with mandibular dysfunction. *J Prosthet Dent* 1985; 53(2):243-247.
161. Miralles R, Dodds C, Palazzi C, Jaramillo C, Quezada V, Ormeno G, Vellagas R: Vertical dimension. Part I: Comparison of clinical freeway space. *J Craniomandib Pract* 2001; 19(4):230-236.
162. Paesani D, Westesson P-L, Hatala MP, Tallents R, Brooks SL: Accuracy of clinical diagnosis for TMJ internal derangement and arthrosis. *Oral Surg Oral Med Oral Pathol* 1992; 73:360-363.
163. Gomes MB, Guimarães JP, Guimarães FC, Neves AC: Palpation and pressure pain threshold: reliability and validity in patients with temporomandibular disorders. *J Craniomandib Pract* 2008; 26(3):202-210.
164. Gaudet EL, Brown DT: Temporomandibular disorder treatment outcomes: first report of a large scale prospective study. *J Craniomandib Pract* 2000; 18(1): 9-22.

Muscle and Pain Facts:

You use 17 muscles
to smile and
43 to frown.

just one question

“What was your experience TENSing?”

The benefits of TENS range from data collection and treatment planning thru case workup, fabrication, and post-delivery recontouring. Patients routinely see astounding results when TENS and Neuromuscular principles are applied correctly. NM dentistry will employ ultra low frequency TENS to electronically massage and relax the muscles involved in head and jaw posture. This is a huge advantage that a NM practitioner has over conventionally trained dentists. We invite you to explore this in our Core I program at LVI. For additional information on TENS please visit www.lviglobal.com.

“ I closed my eyes and relaxed for an hour. It felt like all the strain was out of my muscles.

Dr. Sanjivan Mahara

“ Before TENS my shoulders and neck were tight, after TENS they were very relaxed.

Dr. Linda Difranco

“ I was worried about what it would feel like to TENS after hearing people talk about it, but for me it was one of the most relaxing and comfortable experiences I have had as a dentist! As a matter of fact, after about 25 minutes I get an endorphin release and feel that “runner’s high” and I don’t even have to run to feel it!

Dr. Ali Alibakhshi

“ It felt awesome... like I was getting a massage of my head and neck!

Dr. Zack Bergevin

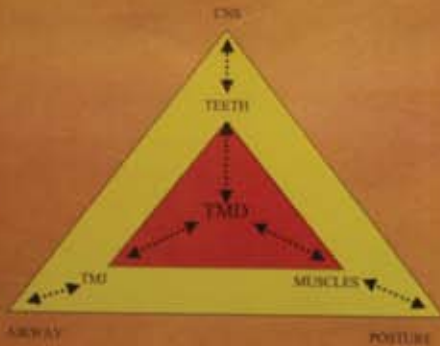
“ I found TENS to be very comfortable and relaxing. My muscles felt less tense.

Dr. Devender Verma

Knowledge Is Power!

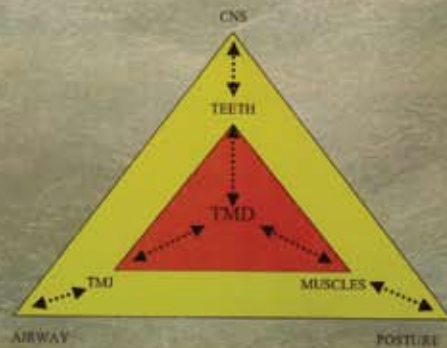
The SCIENCE Behind the Principles of
Neuromuscular Dentistry
are Found Inside These Components.

SAHAG RESEARCH COLLECTION
VOLUME II



A Compilation of Abstracts from
Sahag Mahseredjian, DMD

SAHAG RESEARCH COLLECTION
VOLUME I




A Compilation of Abstracts from
Sahag Mahseredjian, DMD

\$347 as a set or \$197 each.

Order Yours Today!

Call 888.584.3237 or go online at www.lviglobal.com

● *By: Mark Duncan, DDS*



signs and symptoms of NIM

● *Dentistry's best kept secret!*

There are a number of things that we learn from our training to evaluate a patient's oral health and through the years advances in technology have allowed us to do a significantly better job of evaluating our patients. However, as with most things, the key to excellence lies in the fundamentals. Fundamental health history interviews and a fundamental understanding of the complexities of the body are key to providing our patients with the opportunity to accept dental care that improves their quality of life. It is the foundation that provides the dental team the skills to provide care that changes lives daily.



The fundamental signs and symptoms interview of the patient is an essential element in helping patients to understand the connection between the mouth and body and this article will deal with some of the most common connections.

While both signs and symptoms are critical to explore, it is the symptoms that drive the patient to action.

In fact, in both medicine and dentistry it has been shown that it is either the removal of or avoidance of pain that propels a patient to action. Understanding how the emotional trauma of pain symptoms motivates the patient and the logical connection of the signs provide the functional excuse to move forward which is critical in the discussion of comprehensive care.

Some of the most common are also most commonly misdiagnosed. Myofacial pain and headache and migraine are significant issues in the general public and are typically discussed with the physician who generally seek a pharmaceutical or stress management solution. The issue is that it is a physiologic consequence of improper muscle function being driven by a sub optimal bite relationship. This is actually a great thing as with a known cause there is often a solution. Restoring the muscles to physiologic rest is that solution, and it is the responsibility of the dentist to ensure that happens. As Dr. Janet Travell has reported, 90% of pain in the body is muscle in origin and the muscles in the head and neck are responsible for bite, airway, and head posture. Those three issues are critical to address and are tightly inter-related.

Another very common symptom that is reported is grinding. This had previously been thought to be idiopathic and untreatable; however, thousands of patients have had their bruxism stopped by completing NM therapy. As it turns out, the bruxism is the supporting musculature actively searching for homeostasis and doing all they can do to find it, they grind away interferences to arrive at a more



“...the key to excellence lies in the fundamentals.”

physiologically correct resting state. The unfortunate reality is that the proper position is actually more open rather than more closed. As the teeth brux, the vertical collapses, and as often as not, the patient arrives at an end point that is further from a correct bite rather than closer.

Along with bruxism is numbness or a parasthesia in the fingers and hands. Without the perspective to appreciate the connection, it would seem ludicrous to assume that a dental condition would be driving the patient's numbness. On comprehensive health history reviews, it has been repeatedly shown that the numbness in the finger tips is secondary to grinding and with nearly 80% of adult patients being grinders, it is important to understand the connection and share that with our patients. As a part of the bruxing cascade of events is chronic contraction of the muscles in the cervical area, including the scalenes and the SCMs and Traps. Also among the many functions of the muscles of mastication and stomatognathic system, is the support and protection of the airway. If this is compromised it leads to abnormal chronic contraction of the cervical group of muscles. These issues lead to muscles that lie alongside the brachial plexus to chronically pump and contract. This pressure on the nerve plexus results in an alteration of sensation at the end of the nerves distribution – or the hands and fingers.

There are literally hundreds of signs and symptoms that are directly and indirectly related to pathologic bites. The appreciation and vigilant evaluation is essential in optimal patient care. In future issues we will explore other common symptoms that the dental team should screen for and manage with a comprehensive approach; managed with a Neuromuscular approach.



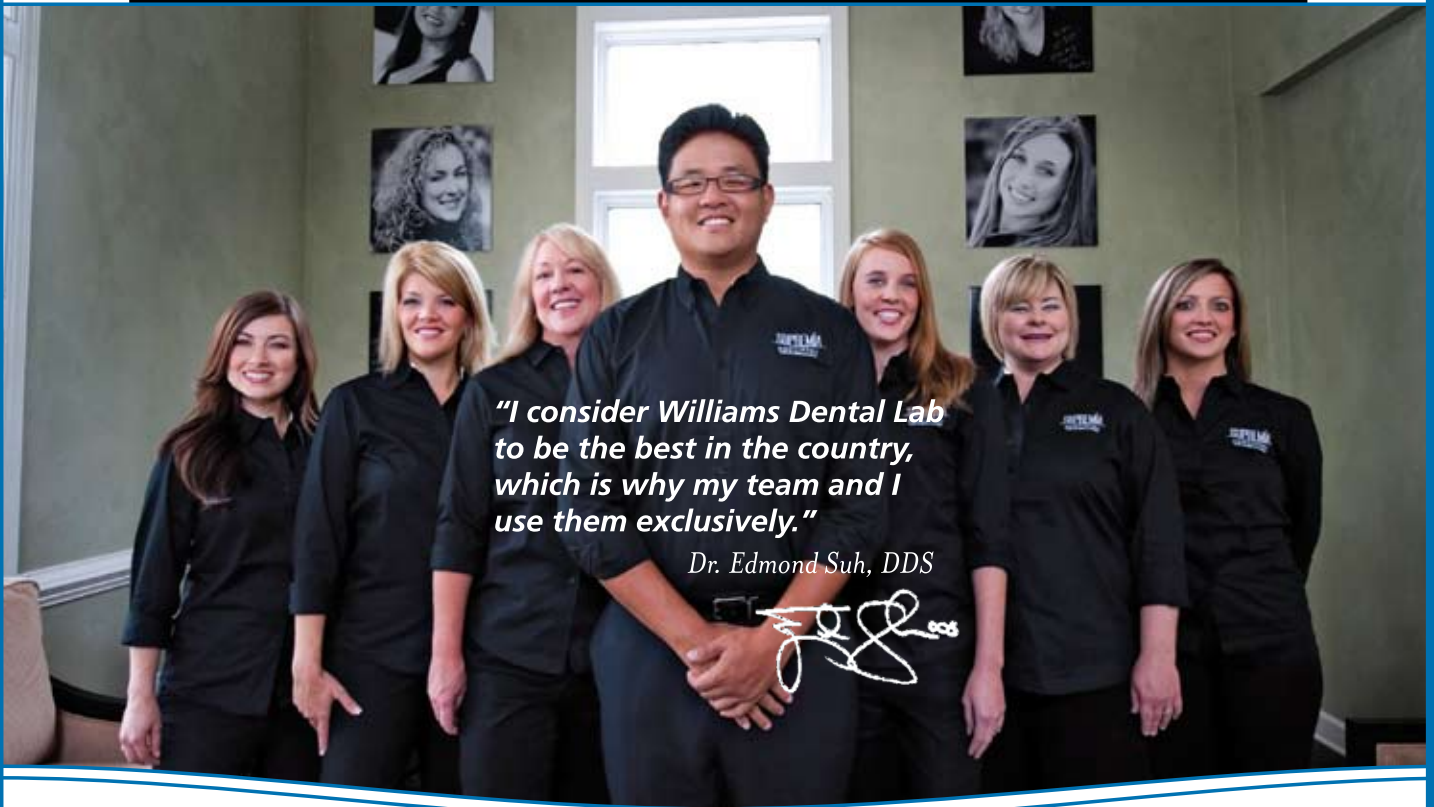
There are literally hundreds of signs and symptoms that are directly and indirectly related to pathologic bites

WILLIAMS

DENTAL LABORATORY

a world of difference...

NEUROMUSCULAR AND AESTHETIC DENTISTRY



"I consider Williams Dental Lab to be the best in the country, which is why my team and I use them exclusively."

Dr. Edmond Suh, DDS

Call Bob at
800-713-5390

- Fast turnaround times
- No additional charges for RUSH cases
- Zero to minimal adjustments at seat appointment
- Always able to facilitate patient's appointment challenges
- A pleasant and precise experience - Easy to work with
- Always able to speak directly to your Technician



800.713.5390 • 408.842.6269 • Bob@WilliamsDentalLab.com
7510 Arroyo Circle • Gilroy, California 95020

A Neuromuscular Perspective on Removable Dentistry

By John Pawlowicz DMD, MICCMO, LVIF



With an aging edentulous population and increasing numbers of baby boomers looking to upgrade their existing dentistry, and replace teeth that have been missing for years, now is the time to take a good look at removable dentistry. Full mouth rehabilitation for this group would mean a new set of dentures, implant retained dentures or, what I see most commonly; the combination of fixed prosthetics, implants and removable prosthetics. Neuromuscular dentistry is a game changer for many dentists who have eliminated the treatment of edentulous and partially edentulous patients from their practice. I understand and have had many conversations with dentists regarding their trepidation to enter back into the treatment of these patients because they fear a poor outcome due to compromised aesthetics, poor fit or retention, but mostly, dissatisfied patients and low financial reimbursement. *It is my belief that offering our patients removable prosthetics is an essential piece that is missing from many Neuromuscular dental practices.* It is incumbent on dentists to provide excellence with regard to form, function, longevity, and aesthetics to all patients who come to us for treatment. This can be accomplished by continuing to push one's self in the area of education, skill, knowledge and advanced hands on training. The education curriculum found at LVI is an essential part of gaining the proper understanding of Neuromuscular Dentistry, and has a natural role in the fabrication of removable prosthetics. We owe to our patients, our selves, as well as our team to include the addition of removable aesthetics to our neuromuscular offerings. *I challenge you, as I have challenged myself, to move forward and learn new skills and become more dynamic in what you can do and offer for your patients and dentistry.*

*“As a Neuromuscular dentist
I am constantly striving for
harmony, symmetry, and homeostasis
of a patient’s body.”*

According to journals BMC Oral Health, 2006, American Journal of Public Health, 2004, and Special Care Dentist, 2012 the patient population (fully edentulous and partially edentulous) is the fastest growing demographic worldwide. The same principles of Neuromuscular Dentistry taught to us when treating our fixed (dentate) patient apply to our removable (partially and fully edentulous) patient. **As there are many terrific advantages to removable neuromuscular dentistry. We can level the maxillary plane of occlusion faster than with a fixed case, merely by fabricating a new denture.** Since we can work on their teeth outside their mouth, we are able to talk to our patients while at the same time working on their teeth; this leads toward building better relationships with them. Coronoplasty techniques and micro-occlusal adjustments can be easier and more efficient. The aesthetics of a case can be managed by changing the tooth design in wax, rather than reworking porcelain on a veneer or crown. There is also a financial benefit to both the patient and the doctor by providing a well fitted and fabricated denture or partial denture. The benefit to the patient comes from less post insertion adjustments, and more comfort. This will then be a benefit to the doctor, because it makes for a satisfied patient who in turn will become a fan, advocate and referral source of your practice.

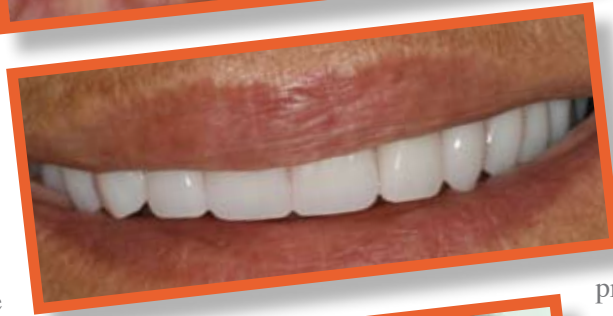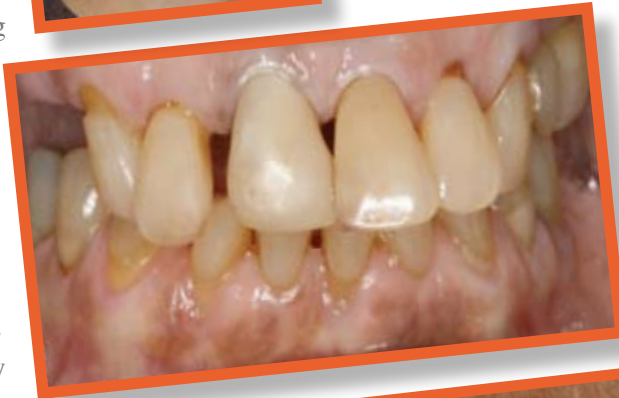The LVI Neuromuscular protocol does not change when the teeth are missing. As mentioned, above, the same principles of Neuromuscular Dentistry

are employed in fixed cases. These principles provide us with the proven Neuromuscular occlusal stability that translates to a superior fit of removable prosthetics. This is a tremendous advantage over the traditionally trained dentist, Prosthodontist or common dentist who struggles with fits that are ultimately the result of the random placement of the jaw relation. Neuromuscular Dentistry attempts to correct the position of the “top block” (the head), body posture, occlusal posture and airway. By correcting the horizontal posture of our patients with a new denture, we also create a better interaction between the postural righting reflexes of the body and an obstructive airway. **In the majority of my neuromuscular rehabilitated full denture and partial denture patients, I will observe an improvement in their forward head posture, as well as an enhancement of their airway.** The correction of the horizontal posture is critical to the success of the denture fabrication. This is accomplished by the proper mounting of the maxillary hamular notch-incisive papilla cast models to the HIP plane. This plane is very important to neuromuscular dentistry, because it represents stable bony reference points which can be used accurately to identify consistent anatomical landmarks. These landmark points give us and as well as our technicians, the ability to have consistency, and accuracy, and therefore, the reproducibility that is necessary to transfer our models and case set-ups. The fully edentulous or partially edentulous patient population allows for easy and accurate capture and reproducibility of these landmarks (the two hamular notches and

“We owe it to our patients, ourselves, as well as our team to include the addition of removable aesthetics to our neuromuscular offerings.”

the incisive papilla of the hard palate) due to the absence of teeth. This in turn is a powerful tool for the analysis of dental occlusion (both good and bad), communication and documentation. Once we have a precise mounting in the horizontal plane, the maxillary teeth can be set to an ideal parallel position with a proper Curve of Wilson and Curve of Spee. The maxilla is the foundation of the occlusion, because of its stationary position, while the mandible is dynamic in its function and is the only bone in the body to have two working joints. The position of the maxillary plane also plays a major role in the alignment and function of the

cranial base and upper cervical vertebrae and their related structures. We must keep in mind that our bodies were designed to have the parallel planes in upright posture. Those planes would be the Bipupillary (Optic) Plane, Otic (Ear) Plane, Plane of Occlusion, Cervical Vertebrae, Shoulders, Thoracic Vertebrae, Lumbar Vertebrae, Sacrum, Pelvis, Knees, Ankles, and Feet. In a healthy body, this parallelism of the skeletal structures will produce harmony in the neuromuscular system. As a Neuromuscular dentist I am constantly striving for harmony,



symmetry, and homeostasis of a patient's body. Any misalignments such as a canted occlusal plane or an abnormal functional habit (grinding or clenching) will result in stress to the patient's stomatognathic system and ultimately lead to disharmony in other parts of their body as well as their neuromuscular system. This holds true for our edentulous and partially edentulous patients the same way it does for our fixed, full mouth rehabilitation patients.

We approach the treatment planning of prosthetics for partially and fully edentulous patients in the same way we approach the treatment planning for a full mouth patient.

The endpoint of a partially or fully edentulous or mixed case can provide you and your patients with the same wonderful, life changing dentistry you have come to expect in your full mouth cases. This growing patient population can benefit from neuromuscular dentistry. Take an LVI removable course this year, and expand your practice into this rewarding treatment area.

See first hand how you can expand in this area with predictable results!

Working Together. By Design.

Instruments designed to work together.

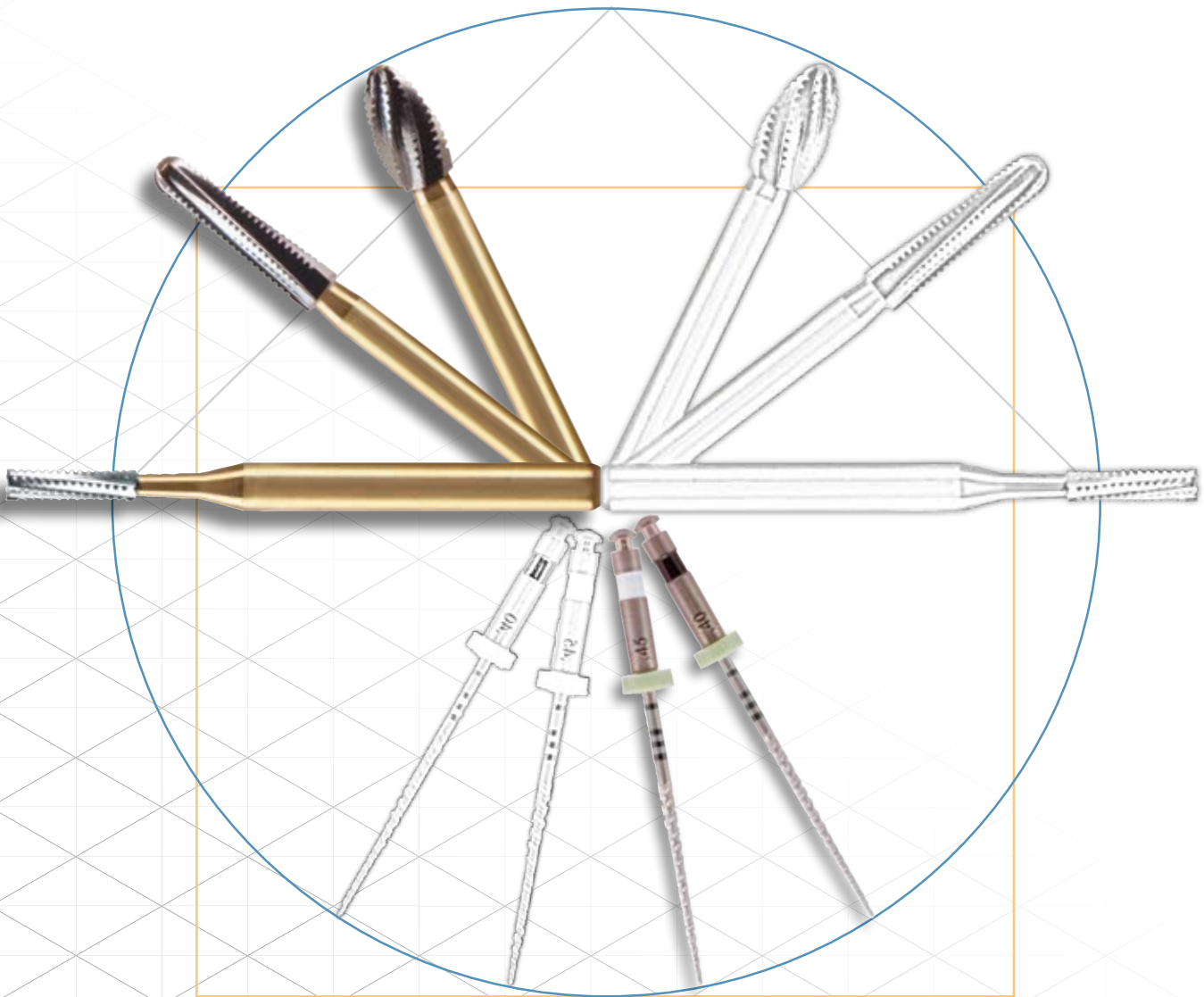
Our rotary and endodontic instruments work together to maximize both procedure efficacy and efficiency while minimizing inventory.

Customized Solutions.

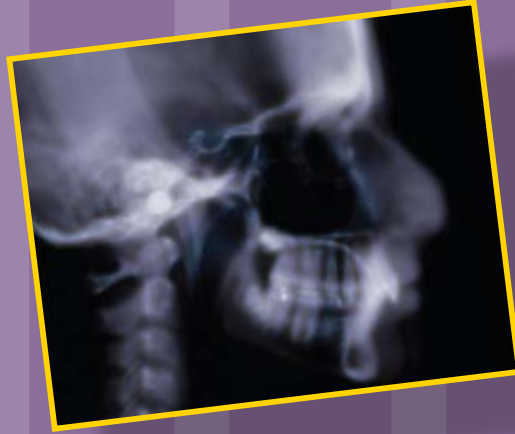For dentists who demand exceptional performance from products designed for the way they practice.

2012 and beyond.

Axis|SybronEndo will continue to help dentists succeed by providing best-in-class local technical support and a portfolio of innovative products designed to work together.



Shamshudin(Sam) Kherani DDS, FAGD, LVIM, MICCMO



The Relevance of Neuromuscular Dentistry in the New Millennium

We have all heard that the only constant we witness in these modern times is “change”. The major point that needs to be recognized about change is that if change is sudden or within a short span of time, it is easily noticed and in many cases appropriately acted upon. On the other hand, if change is slow to very slow, it is not readily noticed, not acted upon. Nevertheless, any such change whether sudden, not so sudden, slow or extremely slow does affect us. Also, preparing for anticipated change can place us all in a better position to deal with such inevitable change.

Although this change is rather slow let me allude to the demographic change that has been affecting us. Let us look at the following trend:

- In 1960, the average 65 year old American was “dead”
- In 1960, if the 65 year old American was alive, he/she would, on average, have 7 teeth in the mouth and they would all be anterior teeth.
- Today, the average 65 year old American is not only alive but, has 17 teeth of which some of which are posterior teeth.
- If today’s 65 year old American reaches his/her life expectancy age (which is nearly 85 years old), that individual will have 24 teeth in the mouth.

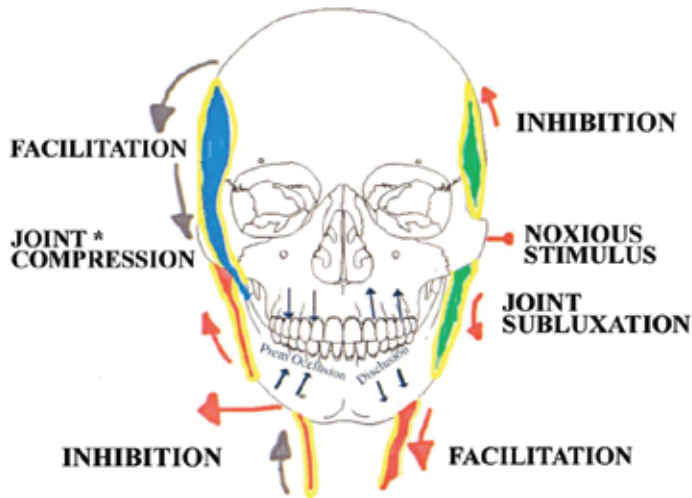
So, we can see that there is this slow change that the average American is keeping more teeth as they ages.

Our dental hygiene programs, with the help of our diligent dental hygienists, are helping average Americans to keep these same teeth in sound periodontal health so that the teeth are firm in the mouth. But, there is a negative side to this as follows.

I would also further postulate based on this report that the higher the periodontal disease incidence in a patient leading to a higher mobility of the existing teeth, the lower the incidence of TMD.

It has been documented in the article “ Missing Posterior Teeth and Risk of Temporomandibular Disorders” by M.Q. Wang, F.Xue J.J Chen, C.S. Chen, A. Raustia that there is a higher incidence of TMD (Temporo-Mandibular Dysfunction) in patients that have more posterior teeth. The opposite is also true in that the less posterior teeth the patient has, the less the incidence of TMD. It has also been documented by Lundeen TF, Scruggs RR, McKinney MW, Daniel SJ, Levitt SR in the 1990 winter issue of J Craniomandib Disorders that the patient population that has the least amount of TMD are the patients who wear full upper and lower dentures. I would also further postulate based on this report that the higher the periodontal disease incidence in a patient leading to a higher mobility of the existing teeth, the lower the incidence of TMD.

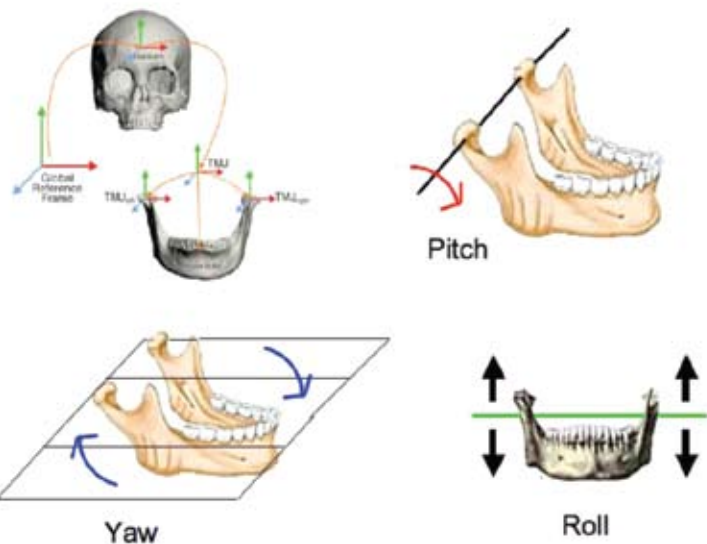
Compared to 60 years ago, dentists are performing less and less clearances (removing all teeth) and placing dentures in our patients mouths until other options are exhausted. More and more patients want us to work with the existing natural root forms in their mouths and furthermore, more and more implants are being placed to complete the full occlusion in the patient's mouth leading to as natural as possible the masticatory apparatus.



Considering the above, it is no wonder that there is an increased incidence of TMD, which will continue to rise unless we address the stomatognathic system as a whole taking into account the health of not only teeth but also of the TemporoMandibular Joints and the Muscles of mastication and posture.

Neuromuscular Dentistry

Neuromuscular Dentistry is the discipline that brings to bear all aspects that would allow the presence of a full complement of teeth in the mouth over long term and at the same time maintain harmony among teeth, TM Joints, Muscles, Posture and the entire complicated Neuromuscular system of the body. In days gone by, when most of our patients beyond the age of 40-50 ended up with either few loose teeth or full dentures, an anatomic model that just paid attention to teeth and seated mandibular condyles allowed them to continue their life to the short ultimate demise.



Today, our patients, at age 50, feel young, look young, have most if not all their teeth, need a definite solution so that they have comfort, longevity and proper function when it comes to the stomatognathic system. Therefore, we need to examine our patients as a whole paying critical attention to their posture, the position of their head and neck, their muscles of mastication and posture, their TMJ and then finally their teeth. In other words, we have to look at the whole body even though we are dentists who are the only professionals

MAKE SUTURING LOOK EASY



**Valued LVI Advantage Members
Get 10% Off All Instrument
& Suture Orders**

	A. TITAN SUTURE CODE	NEEDLE CODE	SUTURE LENGTH	SUTURE SIZE	PRICE
ABSORBABLE PGA Violet & Braided	ATI-6-18-3PGAV	C-6	18"	3-0	\$89.99
	ATI-6-18-4PGAV	C-6	18"	4-0	\$89.99
	ATI-3-18-5PGAV	C-3	18"	5-0	\$115.99
	ATI-6-18-5PGAV	C-6	18"	5-0	\$89.99
ABSORBABLE PGA Fast Absorbing & Undyed	ATI-31-18-3PGAR	C-31	18"	3-0	\$149.99
	ATI-31-18-4PGAR	C-31	18"	4-0	\$149.99
ABSORBABLE PGA Undyed and Braided	ATI-6-30-3PGA	C-6	30"	3-0	\$89.99
	ATI-31-18-3PGA	C-31	18"	3-0	\$115.99
	ATI-6-30-4PGA	C-6	30"	4-0	\$89.99
	ATI-3-18-4PGA	C-3	18"	4-0	\$115.99
	ATI-31-18-4PGA	C-31	18"	4-0	\$115.99
	ATI-3-18-5PGA	C-3	18"	5-0	\$115.99
	ATI-31-18-5PGA	C-31	18"	5-0	\$115.99
ABSORBABLE Chromic Gut	ATI-3-18-4CG	C-3	18"	3-0	\$129.99
	ATI-3-18-5CG	C-3	18"	3-0	\$129.99
	ATI-6-27-3CG	C-6	27"	4-0	\$54.99
	ATI-6-27-4CG	C-3	27"	4-0	\$54.99
ABSORBABLE Plain Gut	ATI-6-27-3PG	C-6	27"	3-0	\$54.99
	ATI-6-18-4PG	C-6	18"	4-0	\$54.99
	ATI-3-18-5PG	C-3	18"	5-0	\$129.99
	ATI-6-27-4PG	C-6	27"	4-0	\$54.99
	ATI-7-27-3PG	C-7	27"	3-0	\$54.99
	ATI-9-18-3PG	C-9	18"	3-0	\$54.99
	ATI-7-27-3PG	C-7	27"	3-0	\$54.99
NON-ABSORBABLE Polypropylene	ATI-1-18-6PPN	C-1	18"	6-0	\$129.99
	ATI-1-18-7PPN	C-1	18"	7-0	\$129.99
	ATI-3-18-5PPN	C-3	18"	5-0	\$129.99
	ATI-3-18-6PPN	C-3	18"	6-0	\$129.99
NON-ABSORBABLE Black Braided Silk	ATI-6-18-3BBS	C-6	18"	3-0	\$49.99
	ATI-6-18-4BBS	C-6	18"	4-0	\$49.99
	ATI-9-18-3BBS	C-9	18"	3-0	\$49.99

New! "Polyglycolic Acid"

- More controlled and reliable breakdown than traditional gut suture
- Less reactivity than gut suture
- Smooth braided surface for ease of knotting

Chromic Gut

- Extended absorption time 90 days
- Tensile strength retained for 14-21 days
- 300 Series stainless steel needles eliminate needle flex, increasing ductile strength
- Resists body enzymes

Plain Gut

- Extended absorption time 70 days
- Tensile strength retained for 10 days
- 300 Series stainless steel needles eliminate needle flex, increasing ductile strength
- Resists body enzymes

Polypropylene

- Non-absorbable
- Synthetic blue superior strength polyolefin
- No tensile strength loss over time
- Reduces inflammation with tissue
- 300 Series stainless steel needles eliminate needle flex, increasing ductile strength

Black Braided Silk

- Non-absorbable
- Minimal tissue inflammation
- 300 Series stainless steel needles eliminate needle flex, increasing ductile strength

**Request a
Free Sample!**



Advanced Razor Sharp Sutures | Features Include:

- Smooth, polished, easy glide surface and uniform thickness
- Superior suture material for advanced wound closure.
- Minimal needle to material transition, reduces suture line bleed.



- Stainless Steel needles eliminate flex and fracture.
- Packaged sterile 12 per package.
- Made in the U.S.A.

trained to restore teeth. The days of looking just at teeth and fixing them in isolation are long gone due to this all-pervasive change that is permeating around us.

As Dr. Bernard Jankelson, the father of Neuromuscular Dentistry said some 50 years ago, "if it is measured it is a fact, if not, it is just an opinion". Neuromuscular Dentistry allows us to measure physiological phenomena, which would then help us bring balance to the stomatognathic system and therefore, also to the whole body as best as possible. Looking at just teeth or just the TMJ is akin to an anatomical model, which is short of the whole relevant picture.

As Dr. Bernard Jankelson, the father of Neuromuscular Dentistry said some 50 years ago, "if it is measured it is a fact, if not, it is just an opinion".

As Dr. Bernard Jankelson, the father of Neuromuscular Dentistry said some 50 years ago, "if it is measured it is a fact, if not, it is just an opinion". Neuromuscular Dentistry allows

us to measure physiological phenomena which would then help us bring balance to the stomatognathic system and therefore, also to the whole body as best as possible. Looking at just teeth or just the TMJ is akin to an anatomical model which is short of the whole relevant picture.

Sleep Breathing Disorders

It is estimated that nearly 20% of Americans suffer from some form of Sleep Breathing Disorders. Such disorders, significantly reduce the life span of the patient via the development of a myriad of diseases. Some of these diseases are fatal. The ironical part is that nearly 80% PCPs (Primary Care Physicians) who are not sleep specialists do not even screen for this highly morbid disorder. So, how is this relevant to dentistry and therefore, to Neuromuscular Dentistry?

In the past, as we performed clearances and delivered complete dentures, we freed up the lower jaw from its retruded position in the oral cavity and furthermore, opening the bite vertically with dentures helped open the airway. Today, most of our patients are keeping their teeth. Their mandibles are distalized due to narrow maxillary arches

You're open.

Wide open.



Secure your practice. Is your patient data wide open? Are you HIPAA and PCI compliant? Do you have a disaster recovery plan? Without the right protection, expertise and preparedness, your practice is at risk. Millions of dollars are lost each year because of a data breach or failures to comply. We offer the critical tools and services to protect you and your practice from a data related catastrophic event. **Act now and call us today for a Free Risk Assessment.**

- + OFF-SITE DATA BACKUP & RESTORATION
- + HIPAA/PCI COMPLIANCE
- + DATA BREACH COVERAGE



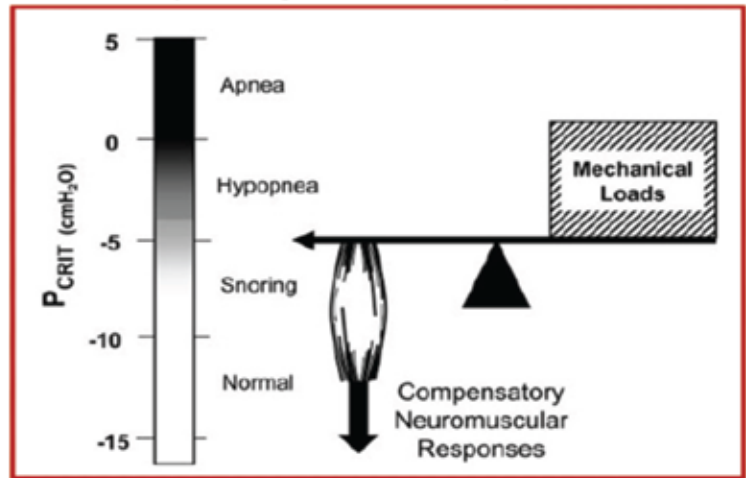
DENTALPRACTICECOMPLIANCE

(800) 871-7640

DentalPracticeCompliance.com

leading to SBD (Sleep Breathing Disorders). Furthermore, as dentists rehabilitate such patients' dentitions by distalizing the mandibles in order to seat the mandibular condyles in the glenoid fossa, it further impinges on the limited airway space. Such manipulation also leads to further "noise" into the NM system leading to reduced ability of the sympathetic tone to keep the airway patent when the patient is asleep and depends on the autonomic system to help.

Fatigued NM complex-leading to physiologic load on system**



Susheel P. Patil, Hartmut Schneider, Jason J. Marx, Elizabeth Gladmon, Alan R. Schwartz and Philip L. Smith
J Appl Physiol 102:547-556, 2007. First published Sep 28, 2006; doi:10.1152/jappphysiol.00282.2006

Once again, Neuromuscular Dentistry helps as the mandible generally comes downward and forward as the mandible comes into the physiologic rest position. Also, such a rest position eliminated the "noise" in the NM system allowing better ability for the autonomic system (the sympathetic tone) to keep

MyPerioPath® periodontal disease test
only from OralDNA® Labs

You probe, you record pocket depths, and you know periodontal disease when you see it. But you also need to know which bacteria are causing the infection. For that kind of objective analysis, choose MyPerioPath®. Target the cause and control the disease. That's the power of MyPerioPath®.

Put the "Power of the Report" in your practice today. Contact your Henry Schein® representative at: **800.372.4346**

oraldna.com

Exclusively Distributed by
 HENRY SCHEIN®
DENTAL

ORALDNA® LABS
Innovations in Salivary Diagnostics
A Quest Diagnostics Company

© 2012 OralDNA® Labs Inc. All Rights Reserved.
OralDNA® Labs is a subsidiary of Quest Diagnostics® Incorporated


the airway patent when the patient is asleep. The diagram below was written in 2007 by Dr. Susheel Patil et al from Johns Hopkins shows that when the mechanical load on the NM system increases, the compensatory NM responses have to kick in. When this system gets overloaded, the balance moves towards increased pressure outside the airway thus collapsing the airway leading to “hypopnea” and eventually to “apnea”.


Finally, I would like to underscore that the need to incorporate Neuromuscular philosophy in treating our patients has never been more necessary than today. One can see that such inclusion is necessary from many aspects that affect our patients’ wellbeing and will become even more important as humans live longer, stay healthier and need to have the pathologic processes that age the body to slow down so that the body can be serviceable for a lot longer period. We can fight or ignore nature for only so long before it catches up with us.

We can fight or ignore nature for only so long before it catches up with us.


Got Torque?

PEOPLE HAVE PRIORITY







surgical led+



IA-400




implantmed



elcomed

wh.com



Awareness of sleep breathing disorders is growing amongst the medical profession, dentists, the media and the public. And it is just as well. It is estimated that OSA affects between 10 and 25% of the population, only 10% of those have been diagnosed and only 10% of those diagnosed are actually being treated and compliant.

Neuromuscular Dentistry
and **Obstructive Sleep Apnea**

A Marriage
of **Mutual**
Advantage

Anne-Maree Cole, BDS, LVIM, MICCMMO

The table below shows the potential extent of the problem:

Country	Population	Estimated OSA 10%	Diagnosed OSA 10%	In Active Treatment 10%
USA	311,000,000	31M	3.1M	310,000
Canada	34,000,000	3.4M	340,000	34,000
Australia	22,000,000	2.2M	220,000	22,000

Figure 1: Potential OSA prevalence

Even if these estimates were 50% incorrect there is still a huge discrepancy between the prevalence, diagnosis and treatment of this profoundly life-threatening condition.

Dentists are in a position to be the number one group identifying these potential patients. Why? Because OSA is a disease of cranio-facial anatomy and who should be the experts in that field? Dentists.

The sad thing is that many dentists fail to recognize the signs and symptoms glaring at us in our patients while we go about repairing the damage that the OSA has done. The question is: Do we ever ask why? Why did that unrestored tooth split? Why did that restoration break? Why are there abfractions? Why is this patient struggling with treatment? Why do they gag when I take an impression? Why is their mandible retruded? Why is their tongue scalloped? Why is this child grinding their teeth away? Why are there bony exostoses around the ridges? Why are those tonsils so huge when there is no infection? Why have they got a deep overbite? Why are they developing into Class II or Class III? Why are there wear facets on their front teeth? Why is there erosion on the occlusal surface of the posterior teeth? Why have they got a narrow palate? Why are their posterior teeth lingually inclined? Why is this patient falling asleep during treatment? Why do they hate going to the dentist – are they frightened of you or are they protecting their airway?

The list could go on and on. To be a good diagnostician, you have to retain your child like curiosity and ask why. Except for blunt trauma, dental breakdown rarely occurs in isolation.

The study of neuromuscular dentistry and an interest in treating temporo-mandibular disorders once again reintroduces dentists to anatomy and physiology.

These dentists acquire a growing awareness of how a compromised airway is root cause to many of the developmental deficiencies witnessed in and contributing to the complexity of the TMD patient. Both TMD and OSA are diseases of a compromised cranio-facial anatomy. Cunali, 2009 showed that 75% of TMD patients also had OSA and 52% of OSA patients also had TMD. This high correlation makes it inevitable that the TMD treating dentist needs to recognize, refer appropriately for a diagnosis to be competent in treating OSA. Similarly dentists treating OSA will find themselves frequently dealing with TMD patients and require a deep understanding of the anatomy and physiology to deliver predictable and favourable outcomes for their patients.

Deficiencies in the cranio-facial anatomy result in cranio-cervical-mandibular relationships, which are compromised. Modern, Western diets and environmental pollutants frequently result in low grade allergies which cause proliferation of lymphoid (tonsils and adenoids) and nasal tissue inflammation and hypertrophy. The net result of this is poor nasal patency obligating the child to become a mouth breather. As soon as this happens, the tongue assumes a low posture in the mouth to enable mouth breathing. A tongue thrust develops to create a seal while swallowing and the tongue fails to take up its rest position within the palate where it would have acted to widen the arch to its genetic potential. Unfortunately the forces from the buccinator muscle continue to act upon the developing dentition in a compressing (narrowing) function. The arch then develops within the neutral zone but the neutral zone is compromised and the end result is a narrow V shaped arch, often with a high palatal vault instead of the optimal broad U shaped arch. And because the roof of the mouth is the floor of the nose, the nasal airway is compromised further.

A compromised airway affects the midface development and the mandible whose growth is predicated by the maxilla is then forced into a more retruded position to enable articulation of the teeth. The lower teeth often crowd and the posterior teeth hypo-erupt due to the pressure of the tongue lying on top of them as the child breathes through their mouth and this results in a deep overbite. As the mandible takes up its retruded position, the functional space of the airway becomes compromised so the body extends the neck forward to maintain the airway and causes a posterior cranial rotation to maintain the horizontal gaze. This is just one of the many adaptations the body will assume to overcome the compromised cranio-facial anatomy.

There is nothing more important to the body than maintaining the airway. We can go weeks without food, days without water but only minutes without air. This forward neck posture and retruded position of the mandible result in a compromised airway but it is an airway none the less and the best airway the body can assume given the compromise. The hierarchy of needs have dictated this posture. The postural reflexes involved in the maintenance of this posture are dictated by the central nervous system as first explained by Sherrington (recipient of the Nobel Prize in Physiology or Medicine 1932). These reflex postural compensations are dictated by the

CNS but maintained by the peripheral neuromuscular system. This change from orthogonal (upright, correct and balanced) posture to reflex driven causes the muscles to be contracted or stretched all the way down the postural chain rather than be at their resting length.

Huxley and Gordon (Nobel Prize for Physiology or Medicine 1963) demonstrated that the resting length of muscle is 2-2.25um per sarcomere and that shortening or lengthening beyond this arrangement will result in fatigue. (Figure 2) Studies have shown that a contraction between 10-25% will completely cut off the blood supply to a muscle (Rasmussen, 1977) (Thomas N. , 1999) - resulting in fatigue and pain. An assumed posture away from orthogonal is fine in the short term but not in the long term. Chronic postural compromise will eventually result in chronic pain as experienced by patients suffering from TMD. (Figure 3)

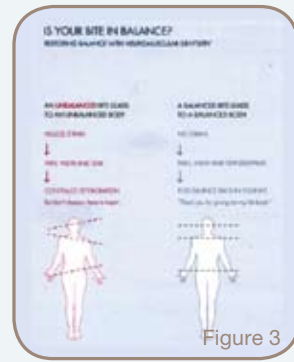

Figure 3

Neuromuscular dentistry recognizes this chronic fatigue as being instrumental to the presenting symptoms of the patient and addresses this compromise physiologically rather than mechanically.

Orthotics are used to support and stabilize the cranio-cervical-mandibular system but the starting position is determined by first relaxing the neuromuscular system through the use of ultra low frequency TENS. Through the use of the J5 Myomonitor, cranial nerves V and VII and XI and C1/C2 receive an impulse every 1.5 seconds. Because the process is neurally mediated, every muscle innervated by these nerves is caused to fully contract for 0.2 of a second and for the remaining 1.3 seconds before the next stimulus, the muscles are allowed to relax because the opposite of contraction is relaxation – the releasing of tension. It is during this relaxation phase that the blood is allowed to once again pump through the blood vessels supplying the muscles bringing with it all the nutrients necessary for healthy normal muscle metabolism and carries away the waste products. Over the period of the TENS the muscles physiologically return to their resting length. This can be verified by various means using the K7 Evaluation system through EMG amplitude, frequency analysis and jaw tracking.

Neuromuscular dentistry thus simultaneously relaxes the cranio-mandibular and the cranio-cervical muscles allowing an improved posture which will be supported and stabilized through the use of a neuromuscular functional orthotic.

So what has this to do with dental sleep medicine and OSA? Well OSA too, is a disease of cranio-facial anatomy, and unfortunately that compromise continues day and night. A fatigued neuromuscular system will be less able to maintain a patent airway when the patient is in their most vulnerable position – lying down and asleep and even more vulnerable during REM sleep when the muscles, including those of the airway, are at their lowest tone. For many patients with TMD and sleep apnea, the wearing of a neuromuscular orthotic on one arch only may not provide adequate stabilization of the mandible to prevent it falling back through

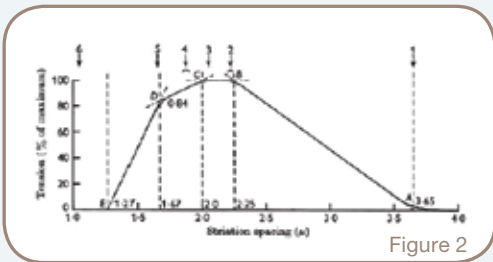


Figure 2

78%

The number of Internet users that access the Web from their mobile devices .

Is Your Practice Mobile Ready?

Page 1 Solutions Offers:

- | | |
|-------------------------|------------------------------|
| Website Design ✓ | Search Engine Optimization ✓ |
| Mobile Website Design ✓ | Google Local/Maps Listings ✓ |
| Patient Reviews ✓ | Custom Copywriting ✓ |

Save over 40% on your mobile site

Get a \$950 mobile site for only **\$575**

Offer expires August 31, 2012

Call **TODAY For Samples**

800-916-3886

www.page1solutions.com

"Thrilled with Page 1. Most of our patients come to us through the Internet. One patient told me this week that no matter what word she typed in, we popped up. That is so cool. Good for you all, and us."

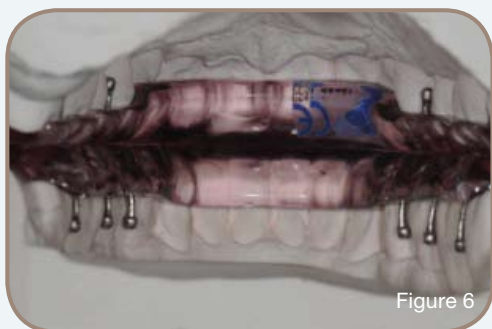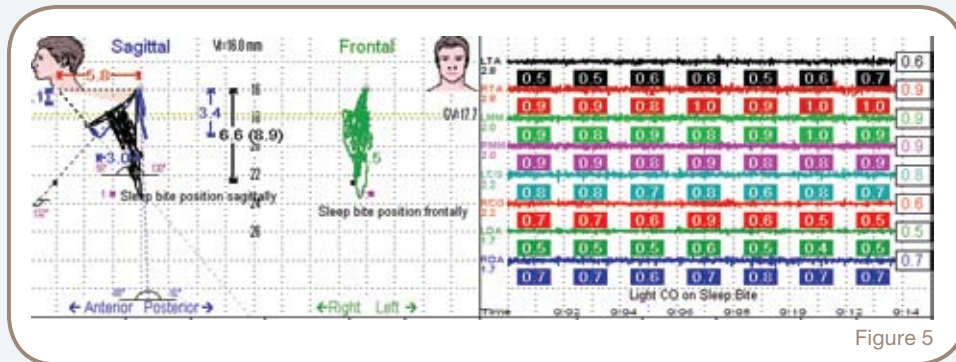
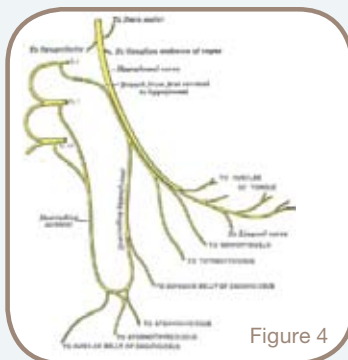
Sue Jenkins

<http://www.mainecosmeticdentistry.com>

PAGE1SOLUTIONS
LLC

www.Page1Solutions.com

800-916-3886



Has his sleep quality improved? **His sleep quality has definitely improved**

Is he snoring? **No, no more snoring :).**

Is he waking more refreshed in the morning? **Yes, he does feel more refreshed in the mornings.**

Is he getting headaches? **No, he has never had any headaches, even prior to wearing Somnodent**

Is he getting any TMJ pain? **No, he has never had any TMJ pain.**

Does he have any trouble getting his teeth back together in the morning? **No, he has no problem getting his teeth back together.**

Has he titrated the appliance? **No, we have never needed to titrate it.**

If yes, why did he decide to do that?

If yes, how far?

If no, did it feel right immediately? **Yes, it felt good immediately, and I was really amazed that it did stop his snoring on the very first night without any titration or adjustments!**

Figure 7

the effects of gravity and despite the physiologic jaw position during the daytime being optimal for the patient, additional support may be required during the night.

The question becomes how should one determine this appliance position to minimize apnea events while asleep? Does it make sense to simply protrude the jaw to 50-70% of maximum or some other patient determined position on a George gauge or does it make more sense to physiologically relax the muscles with the TENS, first, as described above? Ultra low frequency TENS of the cranial and cervical nerves mentioned earlier, either directly or indirectly, through the ansa cervicalis, also stimulates and allows relaxation of the muscles of the airway. (Figure 4) To detorque all these muscles, which have become posturally fatigued prior to determining the bite position to support the neuromuscular system during its most vulnerable time makes physiologic sense to this author. The ability to measure that physiologic response of the muscles in the determined position through the K7 Evaluation system gives the dentist great confidence and objective data to support the starting position. (Figure 5) A titratable appliance without compromise to the volume available to the tongue such as the LVI Lingual-less Somnodent further facilitates a positive and comfortable outcome to the patient and potentially decreases the amount of forward titration necessary for the mandible. (Figure 6)

An LVI Lingual-less Somnodent can be made as a stand-alone sleep apnea appliance for a patient or in conjunction with a daytime neuromuscular appliance for TMD patients. It has been the experience of this author that this approach to dental sleep medicine has been well accepted by the patients who have reported minimal jaw discomfort, a reduction in morning headaches and little trouble returning to their centric occlusion the following day. (Figure 7)





The beauty of neuromuscular dentistry is that it works with the physiology of the patient, not without regard to it. At a time when the physiology is most compromised, anything we can do as dentists to support the physiology, rather than take an already fatigued system and potentially fatigue it further without measuring the physiologic response, simply makes sense. Dentists, as a rule, fail to measure what they do. That is why the medical profession does not like to refer to us as a group. They measure everything in medicine. Now that we can too, it is time the dental profession caught up. What we do can be mechanical, or physiologic. I choose physiologic.

SomnoDent/LVI Lingual-less

- ✓ Significant impact on sleep metrics and airway volume
- ✓ Minimally impinges on precious tongue room
- ✓ Exceptionally comfortable

SomnoDent[®]
SLEEP APNEA APPLIANCE



Make your next SomnoDent a
**SomnoDent/LVI
Lingual-less**

Never compromise patient care
Call SomnoMed for more information.

1.888.447.6673 | usinfo@somnomed.com | www.somnomed.com

Introducing
The LVI Stratos® System

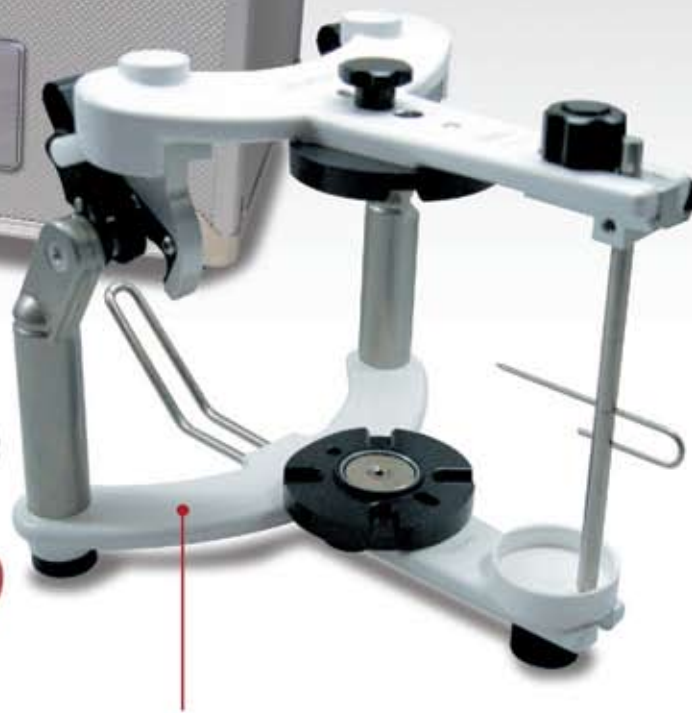A Must to Practice Today's Dentistry



SYSTEM PRICE
\$1,295⁰⁰

Includes carry case, LVI Calibrated Stratos 100,
and LVI Occlusal Analyzer

*The LVI Stratos®
Occlusal Plane
Analyzer accurately
transfers orientation of the
maxillary arch in relation to
the long axis of the body
to the Stratos articulator*



LVI Occlusal Analyzer

- Simple to use
- Adjustable hamular support
- Reproducible mounting technique
- Uses anatomic landmarks not variable soft tissue landmarks
- Fixed incisive papilla pin centers the model

LVI Calibrated Stratos® 100

Based on average anatomical values, the Stratos 100 utilizes fixed 30 degree protrusive and 15 degree bennett angles.

- Stable Easy access design
- Accepts H.I.P mounting accessory
- LVI exclusive calibration
- Magnetic Mounting System eliminates the need to send the articulator to the lab

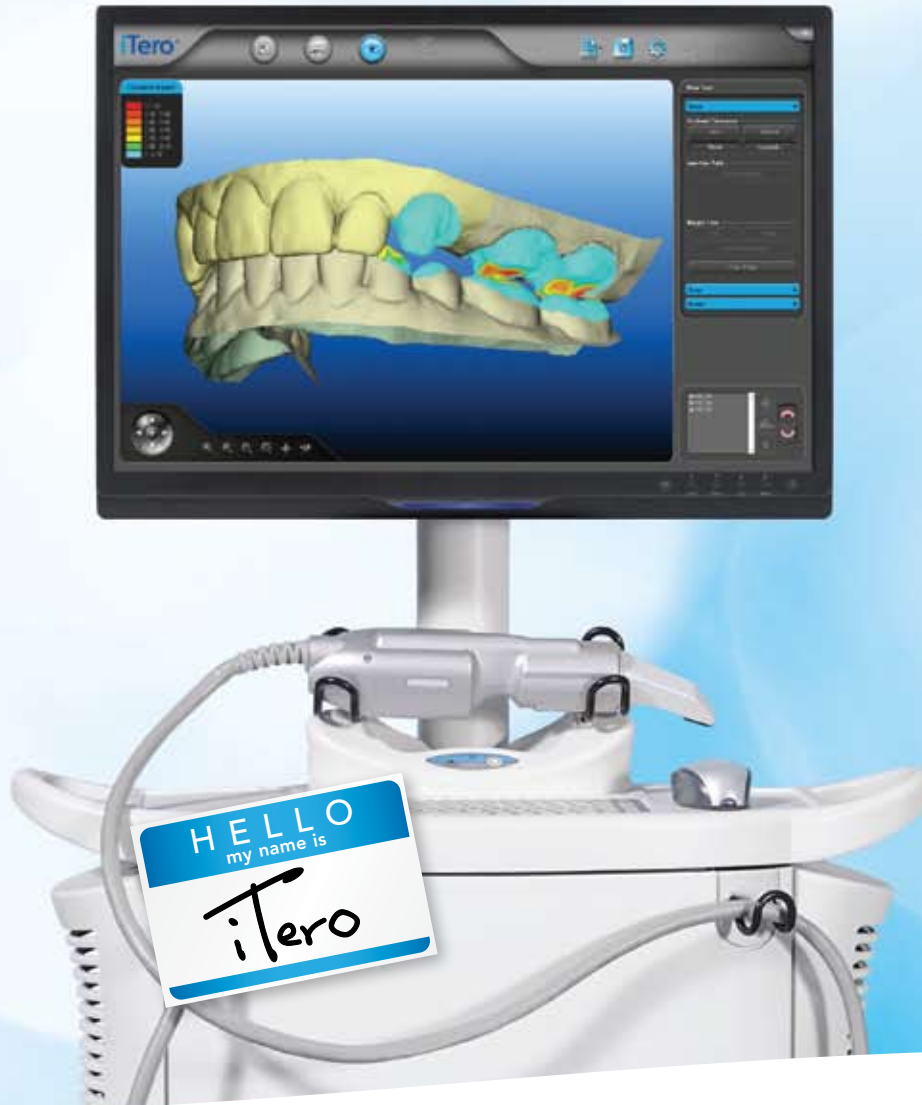To order call **LVI Global** at 888-584-3237

© 2006 Ivoclar Vivadent, Inc. Stratos is a registered trademark of Ivoclar Vivadent, Inc.
LVI is not a registered trademark of Ivoclar Vivadent, Inc.



A BETTER WAY TO MAKE A GREAT IMPRESSION

ANY RESTORATION, ANY MATERIAL, ANY LAB | NO REMAKES OR ADJUSTMENTS | EXCLUSIVE **INVISALIGN** INTEGRATION



Put iTero 2011 Best-in-Class Technology to work and take your practice to the next level.

The proven technology behind the iTero digital scanner takes it far beyond the latest gadget. iTero is a tool designed for everyday use, and one that will change the way you practice. Its efficiency saves time and money by eliminating the cost and hassle of traditional impression materials. Its flexibility offers full-function dentistry – even fixture level implants and orthodontics. And its ease of use means no powder and happier patients.

There's never been a better time to incorporate iTero digital scanning into your practice. Visit www.cadentinc.com for more information on becoming a provider. And start making great impressions today.

EFFICIENT

FLEXIBLE

EASY

iTero™

NEW Programs at LVI

Integrating CAD/CAM Technology in Your Practice

Are you using your CAD/CAM technology to its fullest potential? This dynamic and enlightening course is designed and prepared specifically for the dentist who has already invested in this amazing technology and is now ready to take its usage to the next level. This course presents information regarding how you and your team can increase profitability by improving your CAD/CAM skills and knowledge. During this two day lecture course, many application details and issues will be covered.

The objectives of this course are for the participant to be able to:

- Design and deliver quality CAD/CAM restorations with great aesthetics
- Determine which features/tools work best
- Incorporate appropriate occlusal harmony and interproximal contact parameters
- Optimize time management in tooth preparation, imaging, design, milling, insertion and finishing
- Understand the indications for and application of staining/glazing/polishing principles
- Define the Team's role in marketing, design and integration for successful use of this equipment
- Obtain optimal case acceptance through better treatment presentation techniques
- Be familiar with the advanced techniques needed for quadrants, anteriors and implants
- Be confident in utilizing all software applications

Instructors:

Dr. Terry Yacovitch B.Sc. DDS
Suzanne Bechard-Yacovitch B.Ed

Tuition: \$2,995 Doctors • \$795 Team

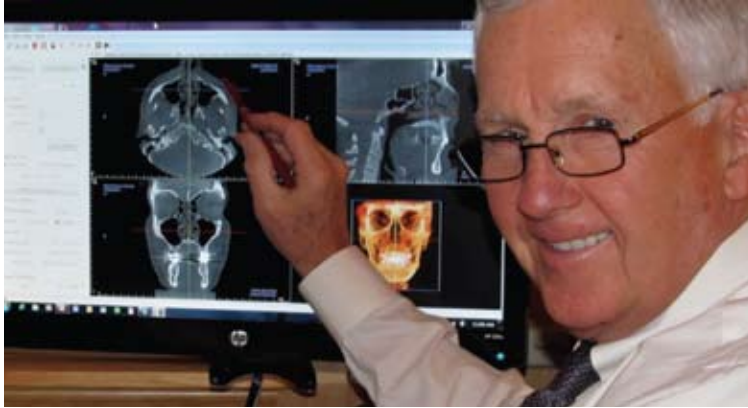CE Credits: 14 CE Credit Hours

AGD Codes: 550

Prerequisites: None

Date: November 16-17, 2012





3D Cone-Beam CT

This course will present information regarding what to look for on CBCT scans and how to obtain optimum results through proper controls and image manipulation. Participants will receive the latest guidelines and protocols for accurate Cervical, TMJ, Airway and Implant procedures along with an enhanced understanding of the norms, 3D head and neck anatomy. Emphasis will be placed on both image manipulation and interpretation. The pros and cons of CBCT Imaging and soft tissue liabilities will also be discussed.

The objectives of this course are for the participant to be able to:

- Utilize techniques for manipulation of 3D CT images for better results
- Implement procedures for CBCT scans for proper Cervical, Airway, TMJ and Implant diagnosis
- Understand how to properly map all axial TMJ images and create the necessary report
- Use 3rd Party Software, Invivo, IVisions, etc for accurate and volumetric airway studies
- Understand how to interpret CTs and MRIs for false positives and false negatives
- How to correlate X-Ray findings with clinical EMG's and jaw tracking

Instructors:

Richard W. Greenan

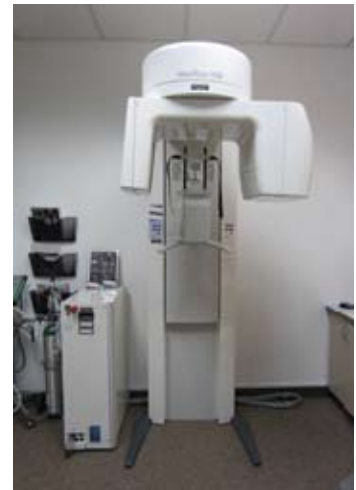Christopher Thornburgh

Chris Wilson

Tuition: \$1,995 Doctors • \$595 Team

CE Credits: 15 Credit Hours

Date: September 13-14, 2012





The Physiologic Approach to Treating OSA

Hundreds of millions of people of all ages around the world suffer from deadly obstructive sleep apnea. Obstructive Sleep Apnea (OSA) has been linked to Cardiovascular Disease, Cerebrovascular Insult, Endocrine Disorders and Obesity. Our medical colleagues are asking for our help, NOW! OSA is considered a disease of craniofacial anatomy so the ONUS is on dentists to identify and help manage OSA sufferers.

Are you prepared to start SAVING LIVES?

This three-day program presents an excellent introduction to evidence-based Dental Sleep Medicine and is designed to prepare dentists and their teams to confidently identify, refer and help co-manage patients with snoring and deadly obstructive sleep apnea. Participants will have the opportunity to learn about the relationships between sleep breathing disorders, neuromuscular dentistry and health. They can discover how to get started, immediately expanding their diagnostic acumen and scope of practice.

The goal of this course is for all participating dentists to become the Dental Sleep Physicians that medical sleep specialists want and need to recognize and refer patients. The possibility of knowing what to do about OSA when you return to your office on Monday morning should encourage you to experience this course!

The objectives of this course are for the participant to be able to:

- Triage patients using flowchart – TMD, OSA, Complex
- Discuss sleep and breathing physiology; normal and pathologic.
- Understand the anatomy and physiology of airway and its relationship to OSA and TMD

- Integrate OSA signs and symptoms into routine dental diagnostics.
- Identify and differentiate OSA sufferers versus snorers with 99% accuracy.
- Discuss why TENSing is important
- Perform OSA Consultation examination/palpation.
- Select snoring and OSA appliances.
- Utilize Combination Therapy - Jointly treating both TMD and OSA at the same time
- Understand medical appliance fabrication and the use of the various instruments available
- Utilize Transition Therapy from OSA to restorative treatment.
- Understand how to make OSA more practical, efficient and profitable

Instructors:

Dr. Bill Dickerson

Dr. Norm Thomas

Dr. Anne Maree Cole

Dr. Sahag Mahseredjian

Dr. John Pawlowicz

Tuition: Doctor \$2,995 • Team \$995

CE Credits:

12 Hours Participation

10.5 Hours Lecture

22.5 Total CE Credit Hours

AGD Codes: 160 - Sleep Apnea & Appliance Therapy (Electives)

Prerequisites: None

Date: May 16-18, 2012 SOLD OUT • September 10-12, 2012

*Hundreds of millions of people
of all ages around the world
suffer from deadly obstructive
sleep apnea.*

**For more information on these courses or to register
please call 888.584.3237 or visit www.lviglobal.com.**



THE *Keys* TO

Understanding NM & OSA

PART VII | *The Metabolic syndrome and Bisphosphonate therapy*

Norman Thomas BDS; MBBS; PhD; FRCD; FADI;
AAOMFPath; DAAPM; Cert MedAc; MICCMO
Director of NM Research LVI

In previous articles on 'Keys to Understanding NM and OSA' it has been repeatedly pointed out that TMD symptomatology including musculoskeletal pain overlaps with that of OSA and that great caution is essential to differentiate between them as well as from other 'Grand Impostor' conditions. Among the latter are osteoporosis, endocrine dysfunctions, diabetes mellitus, chronic alcoholism, blood dyscrasias (hypoxia),hypertension(essential) and mixed pathologies in which TMD may be accompanied by various systemic and neoplastic pathologies association with the Metabolic Syndrome (see Thomas R and Dodhia N (1991) 'Common Emergencies in Cancer Medicine : Metabolic Syndromes J. Natl Med Assoc.83;809-818) in which there is altered acid/base balance ratios of the tissues particularly in neuromuscularly fatigued patients as summarized below. All of this makes for challenge to the diagnostic acumen of dentists who commonly treat NM dysfunction and OSA.

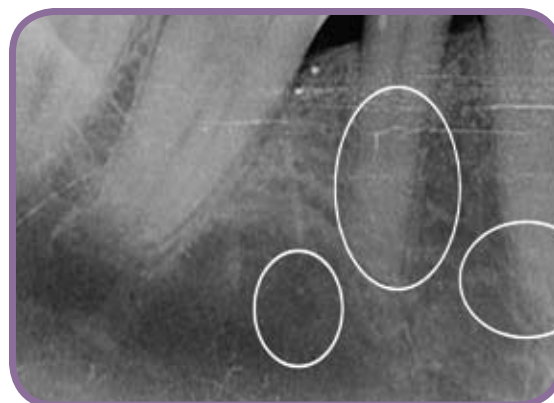Lactic acid is a by-product of inefficient muscle activity. The normal metabolic process of the krebs cycle is not available as there is a lack of oxygenation due to the hypoxic state of the muscles in the non-physiologic bite. As a consequence there is a decrease in the pH and this

further perpetuates a negative cycle. Not only is there a change in ATPases that regulate muscle recruitment of both type I and type II fibers, but there is also bone resorption including abnormal condylar remodeling. In a recent edition of Visions the effect of hypoxia on lysyl

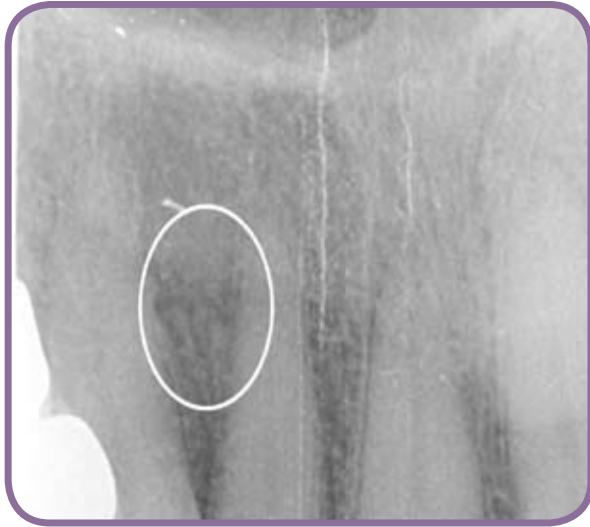
oxidase inhibition and its affect on collagen polymerization was discussed. The hypoxia created in a pathologic bite creates myriad conditions that are deleterious to proper physiologic functioning including the lysyl oxidase inhibition, pathologic bone resorption, the drop in pH, and the hypercapnia that is associated with the hypoxea. Lactic acid is the end product of anaerobic glycolysis accompanying muscle contraction hypoxia from circulatory hypo perfusion in bite accommodation. The ketone bodies formed in chronic alcoholism and diabetic conditions lead to acidosis. The ensuing acidotic pH changes affect the pH dependency of the differing ATPases that regulates recruitment and relaxation of muscle types 1 and 11 as necessary under the prevailing conditions. The pH changes in the blood also bring about bone resorption as in osteoporosis, which is treated by bisphosphonates in order to restrict osseous fractures.

Osteoporosis is the most common bone disease among Americans (55%) of which 80% are females aged 50 years and over. Oral and intravenous bisphosphonates have been shown to be effective treatment essential to controlling hypercalcemia and osteoporosis of the Metabolic Syndrome described above but also for patients with hematological malignancies (myeloblastic leukemia) and solid tumours (myeloma and Burkitt's lymphoma). These agents act through inhibition of osteoclastic activity by binding to hydroxyapatite, thereby inhibiting bone remodeling which is an essential component of NM treatment such as in internal derangement and degenerative jaw joint disease. It is important to understand that metabolic

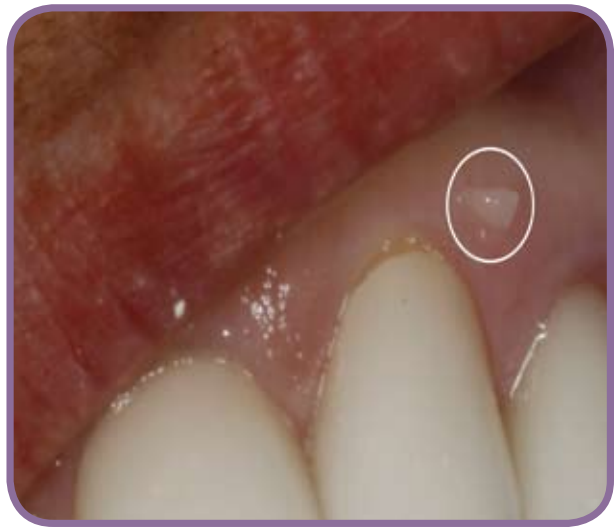acidosis can accompany NM dysfunction due to the production of lactic acid level higher than 5mEq/L with a pH lower than 7.35 according to the Hendersen-Hasselbalch equation where blood and tissue fluid $pH = Pka(7.4).HCO_3^-/H_2CO_3$ and requires compensatory mechanisms of the respiratory center to regulate blood CO₂ levels and/or kidney excretion of H⁺ ions in the urine with accompanying conservation of bicarbonate/chloride/protein ions constituting the anionic gap (Na-(HCO₃⁻+Cl⁻ +protein⁻)) resulting in compensatory increase in sodium and loss of potassium ions through the action of the renin/angiotensin/aldosterone systems. The net result of this alteration in the normal physiology is that the metabolic acidosis creates an imbalance in the physiologic control of the system and creates a cascade of deleterious effects. On January 7, 2008 an alert was issued by the Food and Drug Administration (FDA): "There is a possibility of severe and sometimes incapacitating bone, joint and/or muscle (musculoskeletal) pain in which osteoporotic patients for example have been treated with bisphosphonates. The



ONJ lesions on bite wing radiograph



ONJ lesion in the maxilla



ONJ Sequestrum perforation in maxilla

severe musculoskeletal pain may occur within days, months or years after starting bisphosphonates. Some patients have reported complete relief of symptoms after discontinuing the bisphosphonates, whereas others have reported slow or incomplete resolution”

Between 1995 and 2002 the FDA received reports of severe bone, joint and/or muscle pain that developed in 112 women and four men after starting alendronate (bisphosphonate) therapy. Pain affected bones, joints and muscle all over the

Interested in learning more about LVI and our amazing courses?



Call us at (888) 584-3237,
visit us on the web at www.lviglobal.com
or e-mail us at info@lviglobal.com.



We will send you a complete
course catalog, schedule of upcoming
events and much more.

body and was sometimes migratory. It was often described as “severe, extreme, disabling or incapacitating” musculoskeletal symptoms. The doses of alendronate varied between 5mg/day and 70mg/week with proportional variation in the symptomatology. The onset of pain after starting alendronate therapy ranged from the same day to 52 months. Specialists in endodontics, oral surgery and prosthodontists have wrongly assumed that the myofascial pain arose from routine dental treatment including removeable and fixed orthotics

and often incorrectly remove the orthosis and returns the patient to a vertically overclosed condition with exacerbation of the musculoskeletal symptoms and occurrence off severe depression.

The diagnosis in these cases has been osteonecrosis of the jaw ONJ (Edwards BJ et al (2009) “Pharmacovigilance and reporting oversight in USFDA fast track process: bisphosphonates”. In the next issue I will present the K7 and radiographic findings of which the former have never been described.



Norman Thomas, DDS, PHD, FRCD; FADI, MICCMO, DAAPM, CMAc, M.B., B.Sc (Hons Anat. Physiol)
Norman is the Director of Neuromuscular Research at LVI Global. He is a Professor Emeritus at the University of Alberta. Norman is one of the smartest individuals in dentistry!



Fashioned for fit and performance.

The latest advancement in LED curing lights

- Newly designed light probe for easy access to posterior teeth
- Patented Polywave™ technology to cure all dental materials¹
- Cordless or corded use

For more information log on to ivoclarvivadent.us/bluephasestyle



Bluephase[®] Style
LED CURING LIGHT

100% CUSTOMER SATISFACTION
GUARANTEED!

ivoclarvivadent.com

Call us toll free at 1-800-533-6825 in the U.S., 1-800-263-8182 in Canada.
©2012 Ivoclar Vivadent, Inc. Bluephase, and Polywave are trademarks of Ivoclar Vivadent.
¹All materials known to date in the range of 385 – 515 nm

**ivoclar[®]
vivadent[®]**
passion vision innovation

The Collision Between Professional Attire/Appearance and “Fashion”

By: Mr. Tim Twigg



Relative to an appearance and dress code policy, most dentists require staff to wear uniforms or otherwise look “appropriate and professional” on the job.

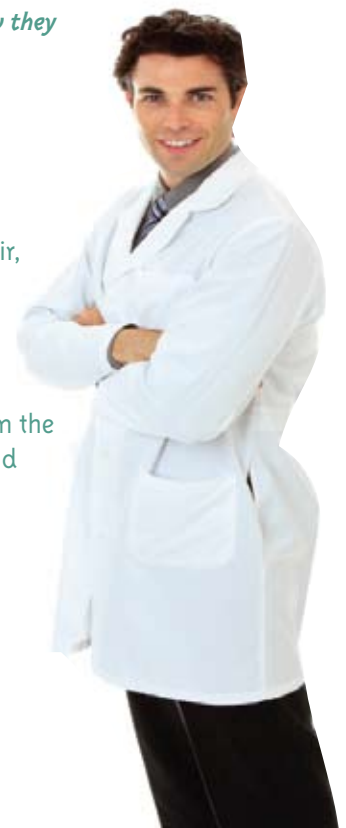Success with neuromuscular dentistry, just like success in other areas of dentistry, is about “elevating your game”. And elevating your game often has both a clinical side and a people side. On the clinical side is: your technology and your clinical skills. On the people side is: verbal skills, appearance, attire/appearance, and customer service. At stake is: patient trust, your reputation, your professionalism, and your perceived credibility.

As you “up-your-game”, you might experience a “collision” between your employee’s personal fashion sense and your desire for professionalism. This is not new; it just seems to be getting worse. From the number of articles written and (believe it or not) lawsuits filed, this is becoming a significant challenge for employers.

Natural questions that come up are:

- *What constitutes professional attire?*
- *What control do I have over what my employee’s wear or how they look and act?*
- *How is their appearance perceived by my patients?*
- *Will there be concerns about the quality of our care?*
- *What, if anything, can I do about it?*

These days with tattoos, body piercings, strange colored hair, “Goth” makeup, and other forms of “body art”, it seems like more and more people are expressing themselves in what some might call unusual “fashion.” Often dental practitioners call it unprofessional. Yet, that doesn’t always stop those who want to express themselves from doing so. In the employment arena, this can surface in the hiring process and ongoing staff management.





So, how do you respond when an applicant reports for an interview wearing what you consider to be unacceptable body art? Can you reject the applicant as a poor fit for your practice on that basis alone? Or, how do you react when a staff member shows up for work with a brand new nose ring or what you consider to be an unacceptable appearance? Can you tell the employee to have the nose ring removed or otherwise change his/her appearance?

Well the good news is that in one recent Court of Appeals decision, a company's interest in fostering a conservative business image trumped an employee's right to wear an eyebrow ring under a local ordinance that prohibited discrimination based on personal appearance. It should be noted that other courts have agreed.

When addressing issues of professional appearance and/or attire, here are a few considerations:

1. In general, employers may have a right to reject an applicant and/or require that existing employees remove or cover up unacceptable body displays.
2. While true in most cases, there are some limitations. For example, employers may be asked to prove that they have a legitimate business reason (i.e. desire to portray a conservative public image) for the requirement, that they apply the standard in a non-discriminatory manner, and that requests for an exception to the policy are considered for certain religious beliefs.
3. You should have a comprehensively written appearance and dress code policy before disciplining and/or otherwise adversely affecting an employee for his/her appearance.

Relative to an appearance and dress code policy, most dentists require staff to wear uniforms or otherwise look "appropriate and professional" on the job. Since employees may have different interpretations about what that really means, be sure you specifically define what you mean by "proper," "appropriate" and "professional." A well-written dress code and appearance policy prevents misunderstandings and clarifies the issue.

Make sure the policy is fair and that it does not unduly place heavier demands on one sex over another, although it is allowable to have different requirements for men and women. For example, women can be asked to wear makeup even though men would not normally be asked to do the same. By all means, carry out your policy consistently with all employees.



EndoSolutions™

www.endosolutions.net

800.215.4245

Distributor of Quality Endo Products

NiTi Rotary Files Hand Files

Obturation Gutta Percha Paper Points

Sonics Handpieces Sonic Shapers

Motors Contra Angles Mini Latch

Restorative Motors Instrumentation

Medical Instruments Touch & Heat

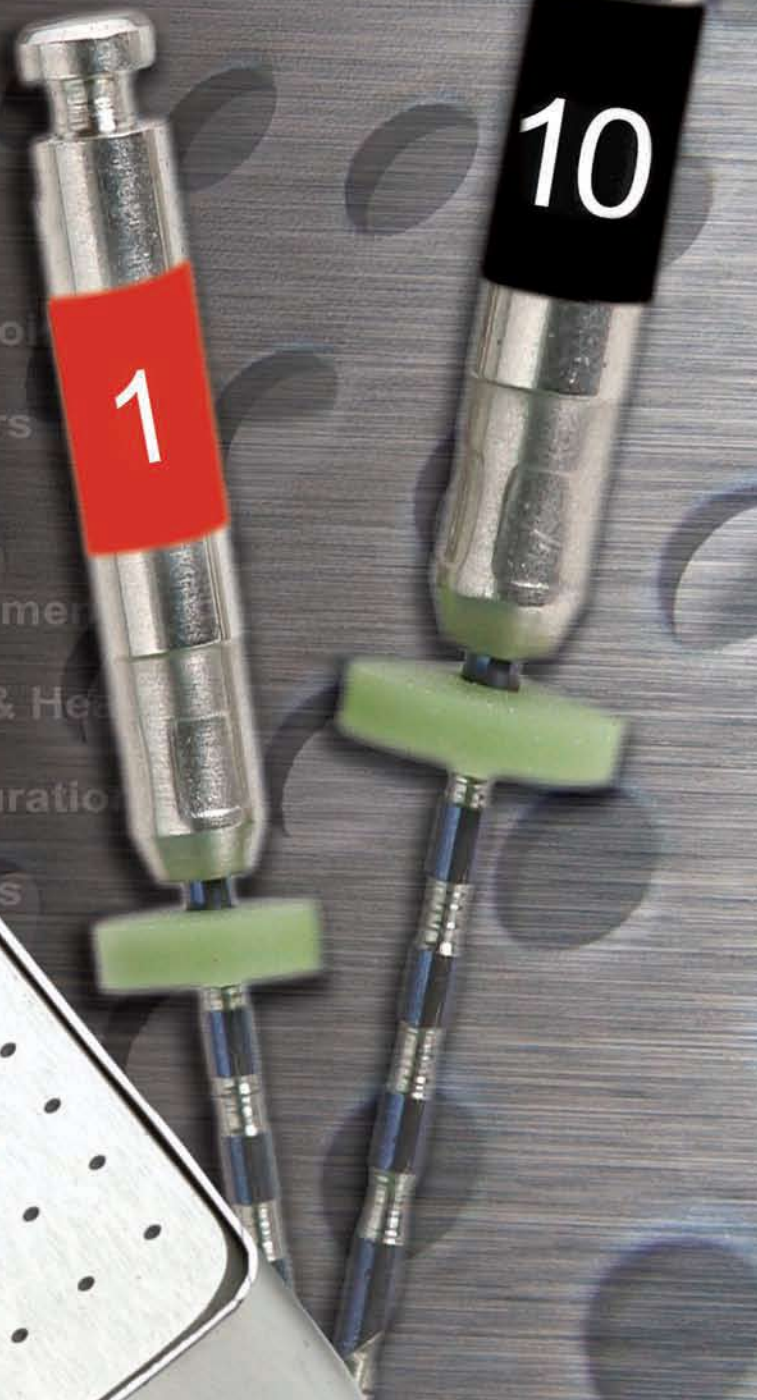
Obturation Instruments

Hand

Control

Restorative

NiTi Rotary



The Endo Experts

As Designed by Dr. Kit Weathers

If you require staff to wear a certain type of uniform, you may be responsible for providing and maintaining the uniform or reimbursing employees for the cost. This will depend upon your individual state laws and whether the uniform requirement is considered "industry standard" or "unique." For example, scrubs or lab coats for certain positions may be an industry standard and could be worn from one job to the next, which relieves the employer of the cost. Other specific uniform requirements, such as black slacks and blue shirts, would probably be considered unique and would require payment as well as care.

One other important aspect to be addressed in your policy is safety or sanitation issues. Take into consideration that some piercings or body ornaments may raise legitimate safety or sanitary concerns. This also would include the type of footwear worn by staff. Open toe shoes, slippers and sneakers could represent a safety issue, as well as long hair hanging loose.

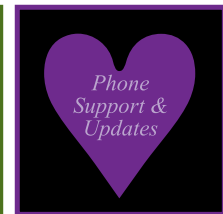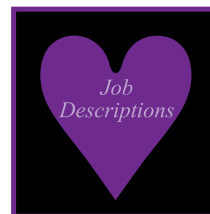Your policy manual should also note that you will attempt to make reasonable accommodations in regard to an employee's sincerely held religious beliefs concerning appearance. Federal and state laws protect employees from discrimination based on religion. The term "religion" includes "all aspects of religious observance and practice, as well as belief," and you can require that proof be provided of the religious belief. Thus, you are required to make reasonable accommodations for the sincerely held religious beliefs of an applicant or employee if at all possible. Reasonable accommodations would include an employee's religious creed that affects ornaments or style of attire.



See it....Solve it....Love it....

Fast, accurate HR solutions...

So you can do more of what you love



Bent Ericksen & Associates • www.bentericksen.com • 800/679-2760

Follow these steps to process a request for an accommodation and reduce the risk of lawsuits:

1. Engage in a conversation to discuss the employees' particular needs.
They should at least know that you will make a sincere effort to accommodate their needs.
2. If an accommodation is made, check periodically with employees to ensure their satisfaction with the arrangement.
3. If an accommodation is not possible, the employer must show that he/she initiated good faith efforts to reasonably accommodate the employee's religious practices but could not do so without "undue hardship." For example, showing that accommodating an employee's religious clothing would cause a significant workplace safety risk.

Your accommodation policy should be in writing and state, among other key points:

- That an accommodation request must be made in writing;
- That it must be submitted directly to the owner/manager (or designated person);
- Whether or not proof of the religious tenet will be required;
- What steps will be taken to resolve conflict;
- That the request will be carefully evaluated taking into consideration:
 1. The cost of the accommodation in relation to the size of the practice,
 2. The number of employees working in the particular assignment,
 3. The number of employees needing the accommodation and
 4. The safety of the person and others.

A reasonable accommodation may include:

- Tying hair back or wearing a hairnet;
- Wearing religious garb in a particular color scheme;
- Modifying dress code requirements to allow for certain deviations;
- Covering up tattoos;
- Removing body piercings, or wearing a plastic retainer in place of a piercing.



Get 2 Free Gifts!

In Just 30 Minutes On The Phone,
We'll Show You How To
Reward Your Patients & Increase Your Profits...

... And We'll Send You a \$50 Hotel Savings Card
Plus a \$50 Dining Discount Card...
Absolutely Free!

Loyal Patient Savings Rewards An Exclusive Powerful Loyalty Program that will . . .

- ▶ Increase your revenue and profits!
- ▶ Enhance your patients' oral health!
- ▶ Dazzle your patients with stunning rewards!
- ▶ Encourage regular visits!
- ▶ Dramatically Reduce no-shows!
- ▶ Reactivate long-lost patients!
- ▶ Bring You a lot more referrals!
- ▶ Turnkey—No extra work for your team!



“Rewarding patients for healthy, profitable behaviors—this makes total sense! We're encouraging our LVI members and Visions readers to use Loyal Patient Savings to reward their patients and increase their profits!”

- William Dickerson DDS, CEO of LVI Global

“Last year, I gave my patients \$4,436,525 in Loyal Patient Savings Rewards! Our patients are healthier and we're more successful! They save on travel, entertainment and merchandise. We reward them for keeping appointments, healthy check-ups, recommending friends, paying in full, and reactivating... talk about win-win!”

- Bill Williams, DDS MAGD



Over 150,000 Selections Including:



**2 Easy Ways to
Schedule Your Free Demo
and Receive Your 2 Free Gifts!**

1. Call 703-609-6442
2. Visit www.LPIDemo.com/LVIVisions



Are You A Dental Inventor?

Got an idea and not sure what to do with it?

We'll help you develop your product, apply for a patent, help get the product manufactured and get it to the marketplace. We'll provide you with management guidance, technical assistance and financing for product development and growth. Dentcubator, LLC is comprised of some of the best and brightest minds in dentistry; a committee of seasoned dental entrepreneurs who have proven market experience ready to help you turn your idea into a successful dental product company.

Dentcubator, LLC • ideas@dentcubator.com

Learn how Occlusion and Aesthetics Go Hand in Hand Core 1

Advanced Functional
Restorative Dentistry
The Power of Physiologic
Based Occlusion

CORE I

is an exciting three-day hands-on course that is designed to show you how to evaluate which cases to treat and how to gain treatment acceptance from your patients using advanced restorative dentistry. This program is designed to increase the level of comprehensive care and enhance the lives of your patients, excite your team and increase the fun and passion you have at work!



Scan codes for a complete list of LVI Courses

ADA CERP® | Continuing Education Recognition Program

LVI Global is an ADA CERP Recognized Provider. ADA CERP is a service of the American Dental Association to assist dental professionals in identifying quality providers of continuing dental education. ADA CERP does not approve or endorse individual courses or instructors, nor does it imply acceptance of credit hours by boards of dentistry. LVI Global designates this activity for 11 continuing education credits.



Academy of General Dentistry
Approved PACE Program Provider
FAGD/MAGD Credit
11/1/10- to 12/31/13



www.lviglobal.com
OR 888.584.3237 FOR INFO

IPS e.max[®] CAD from Aurum Ceramic

Experience the Beauty
and Precision!

For aesthetically sensitive cases, no material performs like IPS e.max[®] CAD. No other laboratory can match Aurum Ceramic[®] in making the most of your IPS e.max[®] CAD restorations.

- A perfect fit in your practice... for strength, precision and aesthetics.
- Beautiful, durable monolithic all-ceramic restorations - Crafted by the leader in Comprehensive Aesthetic and Implant Dentistry.
- Unique optical techniques create the ultimate IPS e.max[®] CAD result.
- Milled utilizing Core3d Centres[®] digitally advanced, five-axis milling technology. Officially validated with Ivoclar Vivadent Inc.
- Indicated for everything from single units to full mouth aesthetic cases.



Precision
and
aesthetics

See the difference for yourself!

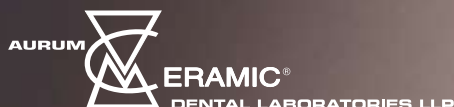Download our reprint of a Case Study (including laboratory/clinical protocols and pictorial review) to see the beauty and precision that can be achieved with IPS e.max[®] CAD milled by Core3d Centres[®]!

Visit www.emaxfromcore3d.com/article or Call Toll Free!



LVI Preferred Lab Partner

Visit us at www.aurumgroup.com



NEVADA, UTAH, NEW MEXICO AND ARIZONA: 1-877-254-5334
WASHINGTON, OREGON, MONTANA AND IDAHO: 1-800-423-6509
OTHER NORTH AMERICAN LOCATIONS: 1-800-661-1169



Designed and Manufactured in the United States